

The background of the cover is a repeating pattern of stylized, overlapping leaves in various shades of green, yellow, and orange-red. The leaves are arranged in a dense, somewhat chaotic manner, creating a vibrant and naturalistic feel. The colors suggest a transition from spring (green) to autumn (yellow and orange).

# **JAFFNA MEDICAL JOURNAL**

**Volume XV No. 1**

**March 1980**












Duplicate MARCH - 1980.



THE JAFFNA

MEDICAL JOURNAL

# VISKEN<sup>®</sup>



Efficient, well tolerated  $\beta$ -blocking therapy in  
Hypertension  
Angina Pectoris  
Rhythm Disturbances

Composition: 1 tablet contains 5 mg prindolol.

Sandoz Ltd., Basle, Switzerland






# THACKRAY

Offers quality instruments  
of every description

with a life time guarantee

- GENERAL SURGERY
- ORTHOPAEDIC
- ENT
- GYNAECOLOGY—OBSTETRICS
- UROLOGY
- THORACIC
- PLASTIC SURGERY



A NAME WHICH CANNOT BE SUBSTITUTED

MANUFACTURED BY:

**Chas. F. Thackray Ltd.**  
**LEEDS, ENGLAND.**

ENQUIRIES TO:

**Aristons Ltd.,**  
**5, GOWER STREET**  
**P.O. BOX 1285,**  
**COLOMBO-5.**

Telephone : 88436, 82102 & 81036

Cables : "Turntide"



# GELUSIL MPS TABLETS

Is more than just an antacid  
It is an **ANTACID**—antiflatulent

**EACH TABLET CONTAINS:**

## PRODUCT INFORMATION

Methylpolysiloxane (Simethicone)	50 mg
Aluminium Hydroxide Gel	250 mg
Magnesium Hydroxide	250 mg

Gelusil MPS is a combination of the antacids, Dried Aluminium Hydroxide Gel, Magnesium Hydroxide plus activated Methylpolysiloxane (Simethicone) Gelusil MPS offers a distinctive therapeutic approach to the treatment of excessive gastric acidity, relief from the discomfort of gastrointestinal gas and bloating. The addition of activated methylpolysiloxane to an antacid formula provides a way to treat gas distention and gastric hyperacidity.

**INDICATIONS:** Gelusil MPS is useful in

- (i) Relieving flatulence and bloating
- (ii) Reducing gastric hyperacidity
- (iii) The adjunctive treatment of peptic ulcer.

**DOSAGE:** One or two tablets between meals and at bedtime and whenever symptoms are pronounced.

**PACK SIZE:** TABLETS—500'S

**WARNER-HUDNUT (LANKA) LIMITED**



# THE JAFFNA MEDICAL JOURNAL

(THE OFFICIAL PUBLICATION OF THE JAFFNA MEDICAL ASSOCIATION)

VOL. XV No. 1

MARCH 1980


## CONTENTS

	PAGE
Editorial .....	1
A Review of Ectopic Pregnancy ..... <i>Siva Thiagarajah</i>	3
Forensic Aspects of Drug Dependence ..... <i>N. Saravanapavananthan</i>	11
New Antibiotics—How and Why ? ..... <i>D. Channugam</i>	14
Four Children with Obstructive Emphysema ..... <i>S. Vyravanathan</i>	17
Coombs—Positive Haemolytic Anaemia and Thrombocytopenia Associated with Hodgkin's Disease <i>N. Nagaratnam, R. G. Rajaratnam, G. Ambepitiya and H. S. R. Wijemanne</i>	23
Neisseria Meningococcus Infective Endocarditis <i>D. Channugam, Rukmal Wijedoru</i>	27
Haemophilia in a Sri Lankan Female <i>N. Nagaratnam, J. Wijesekera, Sarvanantheswari Sinnadorai and K. Mohanaruban</i>	31
News & Notes .....	33

JOINT EDITORS: DR. T. GANESVARAN  
DR. S. YOGANATHAN

---

**CORRECTION**      Surgery in The Jaffna Civil Hospital 1931 — 1933 by Prof.  
SEPTEMBER 79 ISSUE      Milroy Aserappa Paul "Souttas had done this operation in  
1926 with dramatic success". P. 17 Line 2 & 3.



more than  
just plain  
antacid in a  
teaspoonful  
with

## **mucaine** \*

(oxethazaine in alumina gel  
with magnesium hydroxide,  
Wyeth)

### **Added benefits of dual action**


- rapidly relieves pain of  
inflamed gastric mucosa
- buffers excess acid

### **Convenient and economical low dosage**

- sustains relief up to 6 hours  
after each 5 ml dose

### **Unusual safety and virtually nonsystemic**

- topical action avoids  
anticholinergic side effects
- does not mask the symptoms  
of pathophysiological conditions

 **Wyeth International Ltd.**  
Philadelphia, Pa. 19101 U.S.A.  
\* Trade mark

**Local Agents—M/s Muller & Phipps**  
3rd Floor—Chartered Bank Building  
Col.—1



# Editorial . . . .

## Stokes Report

Dr. J. F. Stokes, WHO consultant in medical education, was in Sri Lanka recently on a short term assignment to advise the government on postgraduate medical education in this country. The report now known as the "Stokes report" is being studied by the government. Dr. Stokes has visited all major hospitals and reported on merits and drawbacks of each hospital for postgraduate training.

Dr. Stokes speaks of Jaffna hospital as a hospital that has, rundown despite an enthusiastic consultant staff. He has commented that the hospital was not clean, security poor, with a general lack of administration and seriously deficient nursing staff. He concludes that the general hospital in Jaffna is unsuitable for postgraduate education at present. We are not at all surprised that such a report has been made. Consultant staff of the general hospital Jaffna has repeatedly called for early remedial measures as this hospital is to be used for undergraduate training from July 1980.

It has now been realised that the Jaffna hospital due to lack of a comprehensive long term plan has become an overcrowded slum like hospital. Due to its situation and the pattern of population in the province this hospital has to remain the premiere health institution of the province. No other hospital can take its place even though the base hospitals at Tellipallai, Point Pedro, Vavuniya and Mannar have to be developed into specialist centres of

modest dimensions in the near future. It is in this context the project report of the consultants committee of G. H. Jaffna was considered and accepted as policy by the D. H. S and the Hon. Minister of Health. The policy remains to be strengthened at cabinet level and implemented early.

The Stokes report provokes further thought on our system of planning and medical administration. The whole question of managerial functions in the Health Department may have to be reconsidered to avoid wasteful expenditure and to achieve maximum results. The services have expanded and correct planning requires epidemiological studies and specialised knowledge in many fields of medicine. A strong advisory body consisting of specialists in many fields has become essential to formulate plans programmes and policies for a S H S division. Management of funds to obtain maximum benefits requires skill and — knowledge presently not available in the department of health. It is not too early to obtain the services of professional career accountants trained in managerial skills to meet the tasks ahead.

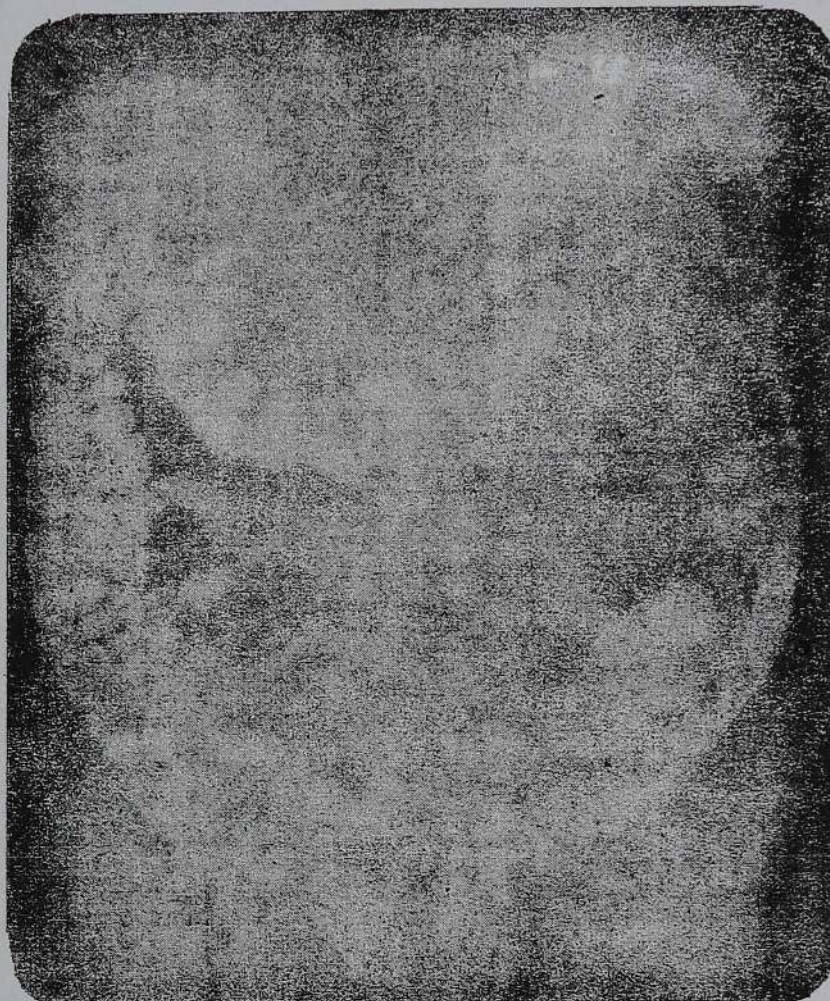Ref. Postgraduate medical education in Sri Lanka

No. SE A/Med. Edu /367 of 18 -1-80.

by Dr. J. F. Stokes M. D., F. R. C. P.,  
F. R. C. P. (E)




## A major indication for «Librax» Roche



The patient complains of abdominal pain, diarrhea alternating with constipation, nausea, sometimes vomiting.

Report of radiological examination after barium meal (M.K., born 1916): Spastic colon with acceleration of gastrointestinal transit; as little as one and a half hours after the barium meal, the head of the column had already reached the rectum, still with quite good filling of the stomach and regular, progressive filling of the ileum. Marked spastic haustra in parts of the colon, but no coarsening of the mucosal pattern.

Wayne performed a double-blind trial with «Librax» and placebo, and laid stress on the effect on anxiety-tension, abdominal pain and nausea, and on the advantages of such a combination over anticholinergics alone in the treatment of functional gastrointestinal disturbances.

Other indications for «Librax»	Gastric and duodenal ulcer (adjuvant treatment), gastritis, duodenitis, biliary dyskinesia.	Dosage: 2–4 dragées daily. Start with 2 dragées daily in elderly patients. Precautions: Alcohol should be avoided. Caution is required in prostatic hypertrophy.
Contraindication	Glaucoma.	
Reference	Wayne, H.H.: A Tranquilizer-Anticholinergic Preparation in Functional Gastrointestinal Disorders: A Double-Blind Evaluation, <i>Calif. Med.</i> 111, 79–83 (1969).	The active substances of «Librax» are: 5 mg 7-chloro-2-methylamino-5-phenyl-3 H-1, 4-benzodiazepine 4-oxide (chlordiazepoxide) and 2.5 mg 1-methyl-3-benziloyloxyquinuclidinium bromide (clidinium bromide).
	F. Hoffmann - La Roche & Co. Ltd, Basle, Switzerland	For detailed prescribing information please consult the packing slip or The «Roche» Vademecum. «Librax» is a Trade Mark

**Sole Agents: Messrs. A. Baur & Co., Ltd., P. O. 11, Colombo 1.**

SCHWABE



# A REVIEW OF ECTOPIC PREGNANCY

*A Four Year Survey at General Hospital, Jaffna 1976 — 1979*

By

DR. SIVA THIAGARAJAH

An ectopic pregnancy occurs when a fertilized ovum implants in a site other than the normal uterine cavity. The name ectopic is derived from the Greek word 'Ektopia' meaning displacement, thus referring to a "displaced" pregnancy. The commonest site is tubal. Other sites include the interstitial part of the fallopian tube, the cervix, the ovary and abdominal cavity.

Ectopic pregnancy has been one of the most widely discussed subjects in Medical literature its history spanning over ten centuries. It was clearly described by Abulcasis in 936 A. D.; Where he records a case in which foetal parts escaped through the abdominal wall of a woman by suppuration. In 1693 Paris physician Busiere reported an unruptured tubal pregnancy found in a woman prisoner after her execution in the guillotine. In 1731 English Obstetrician Gifford considered that extrauterine pregnancy resulted from some vivid emotion or fright that occurred during coitus. At that time the subject of ectopic pregnancy was only academic; treatment was unavailing and a fatal outcome was the order of the day.

The first recorded successful surgery for ectopic pregnancy took place in 1759 in America. During the first 80 years of 19th century, 25 out of 30 who underwent abdominal operations for ectopic pregnancy died and surgical methods fell into disrepute.

In 1885 British Surgeon Lawson Tate deliberately and successfully operated on a ruptured tubal pregnancy, and revived abdominal surgery for all time.

## MATERIALS AND METHODS

The material utilized in this study consists of a consecutive series of 48 ectopic pregnancies encountered per 25,838 deliveries at Government General Hospital, Jaffna; during a four year period from 1st January 1976 to 30th November 1979. Of these 44 cases were diagnosed or suspected as ectopic pregnancies before a laparotomy was performed. Two cases were discovered at a laparotomy performed for some other suspected gynaecological condition. The other two cases were from the Obstetric and general Surgical Wards.

16 patients admitted in a state of severe shock were taken up for emergency surgery and another 13 were operated within 6 hours of admission.

There was one death due to irreversible shock following internal haemorrhage.

Their incidence, mode of presentation, pre disposing causes, clinical findings and findings at laparotomy are analysed in this study.

## MORTALITY RATES

Ruptured ectopic pregnancy is the gynaecologist's most critical emergency. Breen (1970)<sup>1</sup> states that ruptured ectopics account for 6-7% of all gynaecological deaths. In England and Wales deaths from ectopic pregnancy is classified as maternal death and accounts for 7% of all maternal deaths (Burke, 1976).<sup>2</sup> Brenner (1977)<sup>3</sup> reports a mortality of 10%.

Reported mortality rates among ectopic vary widely. Harralson et al (1973)<sup>4</sup>



recorded one death in 96 patients, Douglas (1963)<sup>5</sup> reported a mortality of 1.2% in U. K. and Balfour (1974)<sup>6</sup> found a mortality of 7% in Nigeria. In this series the mortality is 2%.

### INCIDENCE

The incidence of ectopic pregnancy is recorded as the number of ectopics per deliveries after 28 weeks of gestation during a prescribed period. The incidence varies from place to place. Figures vary from 1 in 300 deliveries to 1 in 1000 deliveries (Jeffcoate, 1967),<sup>6</sup> that is

abnormalities are either structural (gross or microscopic) or functional.

Structural abnormalities are either due to congenital anomalies like diverticulae etc. or tubal damage following infection or surgery.

### Infection:

Previous pelvic inflammatory disease is important aetiological factor. Unrecognised tuberculous salpingitis is probably an important cause, and so is the recognised disease which has been treated by antibiotics (Jeffcoate 1967).<sup>6</sup>

**Table I: Incidence of Ectopic Pregnancy:  
General Hospital Jaffna 1976 — 1979**

Year	No. of Ectopic Pregnancies	Total Deliveries	Percentage
Jan. - Dec. 1976	19	6,250	0.30%
Jan. - Dec. 1977	8	6,194	0.13%
Jan. - Dec. 1978	10	6,954	0.15%
Jan. - Nov. 1979	11	6,440	0.17%
Total:	48	25,838	0.19%

0.1 — 0.33%. Breen (1970)<sup>1</sup> reported an incidence 1 in 87 deliveries in New Jersey, while Douglas (1963)<sup>5</sup> recorded a very high incidence of 1 in 28 in the West Indies. Burke (1976)<sup>2</sup> reported 1 per 250 deliveries in U.K. (0.4%). In this series there is an incidence of 48 per 25,838 deliveries (0.19%). The recorded rise in incidence in recent years (Breen 1970)<sup>1</sup> is due to the promiscuity of our younger generation, increased incidence of venereal disease and residual tubal pathology resulting from wide use of antibiotics in the therapy of pelvic inflammatory disease.

### AETIOLOGY

An ectopic pregnancy implies abnormal reproductive function. Abnormalities associated with the fallopian tube account for many ectopic pregnancies. These

Any form of salpingitis damages the tubal lining of ciliary epithelium and antibiotics though may prevent tubal occlusion do not always prevent damage to the epithelium.

Uterine infections are known to extend to the tubes as well. Peruterine sepsis, septic abortion and even a subacute asymptomatic post abortal infection can damage the tubal epithelium.

Pelvic infections or appendicitis causes peritubal adhesions and tubal damage. The relationship between appendicitis and ectopic pregnancy is well known; ectopic being significantly more frequent on the right side (Sandmire and Randall 1959,<sup>7</sup> Grant 1962,<sup>8</sup> Douglas 1963),<sup>5</sup> In our series 26 out of 41 tubal pregnancies were on the right side.



The possible aetiological factors in 26 patients in this series are given in Table II,

**Tubal Surgery:**

Ectopic pregnancy may follow tubal ligation. The Pomeroy's and Madlener's

is well recognised. Three patients in our series had a Lippes loop in situ when they presented with ectopic pregnancies. It is reported that ovarian pregnancies in women wearing IUCDs is higher. IUCDs protect the wearer against intra uterine pregnancy, and to a lesser extent against

**Table II: Possible aetiological / predisposing factors in 26 patients**

Available Previous History		Patients
1. Infections - Salpingitis	.....	2
Gonococcal	.....	—
Appendicitis	.....	2
Peurperal sepsis	.....	3
Abortions	.....	9
2. Tubal Surgery Failure of Tubal Ligation	.....	2
Recurrent Ectopic.	.....	1
3. Intra uterine device in situ	.....	3
4. Investigated for subfertility with tubal insufflation	.....	4
Total:		26

techniques are those commonly implicated Haynes and Wolfe (1970)<sup>9</sup> followed up 489 tubal ligations and reported three ectopic pregnancies. Individual cases have also been reported by Harralson et al (1973).<sup>4</sup>

In this series of 48 consecutive ectopic pregnancies that we have treated there were two patients who had undergone previous tubal ligation.

Also reconstructive tubal surgery increases the risk of ectopic pregnancy.

The incidence of an ectopic pregnancy recurring a second time is approximately 5-10% (Grant 1962).<sup>8</sup> In this study over a period of 4 years there was only one such instance.

**Modes of Contraception:**

The association between intrauterine contraceptive devices and ectopic pregnancy

tubal pregnancy but no protection is afforded against an ovarian pregnancy (Tietz; 1966).<sup>10</sup>

Bonner (1974)<sup>11</sup> reported the incidence of ectopic pregnancy among users of progesterone - only oral contraceptives. Hawkins (1974)<sup>12</sup> believes that the relationship is analogous to that between IUCDs and ectopics. None of our ectopic patients were on the pill at the time of presentation. A diagnosis of ectopic pregnancy should not be excluded because the patient is having an IUCD or taking oral contraceptives.

**Tubal Insufflation:**

There is an increased incidence of ectopic pregnancy among women investigated for infertility (Grant, 1962;<sup>8</sup> Wyper, 1962).<sup>13</sup> Four patients in this series were earlier investigated for infertility with tubal patency tests.



**CLINICAL PRESENTATION**

The age of the 48 patients in this series ranged from 18 to 40 with the largest number occurring in the 21-30

Vaginal bleeding characteristically follows pain, but not always so.

Sometimes amenorrhoea is not mentioned by the patient. A careful menstrual

**Table III: Age Incidence in 48 cases of Ectopic Pregnancy**

Age in years	No. of Patients
15 - 20	2
21 - 25	15
26 - 30	17
31 - 35	9
36 - 40	5
41 - 45	0

years age group. (Table III). Evaluation of the age distribution substantiates the fact that a woman who is capable of conceiving is capable of having an ectopic pregnancy.

**Symptoms:**

The most consistent symptom of ectopic pregnancy is abdominal pain,

history reveals that the majority of the patients have missed a period.

The presenting symptoms of the 48 cases are given in Table IV.

**Signs:**

In severe cases the patient is in a state of shock with rapid thready pulse, lowered blood pressure, extreme pallor,

**Table IV: Presenting Symptoms of 48 Patients of Ectopic Pregnancy**

Symptoms	Number of Patients
1. Abdominal Pain	44
2. Period of Amenorrhoea	42
3. Vaginal Bleeding	26
4. Fainting Attacks / Giddiness	13
5. Morning Sickness	11
6. Shoulder Pain	10
7. Backache & Dysmenorrhoea	1
8. Retention of Urine	1

which may be generalised or localised to one or other iliac fossa. The pain may be severe but often passes once intra abdominal bleeding becomes significant.

air hunger, cold clammy skin and even a sub normal temperature. 16 patients in this series admitted in a state of severe shock, were taken up for emergency surgery.



The most consistent finding is abdominal tenderness on palpation; usually generalised but may be confined to one iliac fossa. Rebound tenderness may be present. Signs of free fluid as dullness in flanks less common.

Many are of the opinion that a vaginal examination should not be carried out when an ectopic pregnancy is

Undue faith is placed in ultrasonography. Kobayashi et al (1969)<sup>14</sup> had shown that ultrasonography is unreliable for diagnosing ectopic pregnancy. There is a high incidence of false positives and and even worse false negatives.

Culdocentesis, culdoscopy, colpotomy and laparoscopy are useful aids to diagnosis. These were not done in our

Table V: Presenting Signs in 48 cases of Ectopic Pregnancy

Signs	Number of Patients
1. Tenderness in Abdomen	44
2. Tenderness in moving cervix	41
3. Guarding	24
4. Shock	16
5. Fullness of Pouch of Douglas	16
6. Flank Dullness	14
7. Uterine enlargement (8-10 wk. size)	9

suspected. When a vaginal examination is carried out the usual findings were acute tenderness in moving the cervix, tenderness in both or one fornices, mass in the adnexae or pouch of Douglas or an enlarged uterus. The presenting signs of 48 patients are listed in Table V.

### DIAGNOSIS

The most important aids to the diagnosis in this series were the history and the physical signs elicited at clinical examination. Examination under anaesthesia is never justifiable. Severe bleeding can be precipitated by palpating the affected tube. (Jeffcoate 1967)<sup>6</sup>

There are additional aids to diagnosis which may be employed in patients who are not acutely ill.

Radiology is contra indicated by the possibility of a uterine pregnancy.

patients. Surgery had been the only way to confirm diagnosis.

### TREATMENT

The immediate treatment of the patient depends on the general condition and situation at the time the diagnosis is made. Resuscitation of shocked patients commenced before operation but surgery should not be delayed. Both should really go hand in hand. In the severely ill minimum of surgery should be done to secure haemostasis.

In this series of 48 patients, 16 admitted in a severe state of shock were taken up for Emergency Surgery. All patients received 1000-2500 ml of blood transfusion. 13 patients with rupture, not in shock were operated within the next six hours. 11 cases of diagnosed ectopics were operated within 48 hours. 4 cases with a slender suspicion of ectopic, taken up at leisure and 4 more unsuspected cases turned out to be ectopic at laparotomy



## FINDINGS AT LAPAROTOMY AND SURGERY

Among the 48 cases presented there were 41 tubal, 4 abdominal, 2 ovarian and one interstitial pregnancies.

### Tubal Pregnancy:

Out of the 41 tubal pregnancies 25 were found on the right side and 16 on the left.

The common surgical procedures followed were (1) Unilateral salpingectomy and (2) Unilateral Salpingo-oophorectomy. It is not always possible to salvage the ovary if it is involved in a haemorrhagic mass. Also leaving the ovary on the affected side increase the risk of subsequent ectopic pregnancy (Jeffcoate 1967)<sup>6</sup> Bender (1956)<sup>15</sup> reported that removal of ovary on the affected side increased subsequent fertility.

### Abdominal Pregnancy:

4 cases of abdominal pregnancy were encountered in this series among 48 ectopic pregnancies.

One of them was a case of advanced abdominal pregnancy. A persistent transverse lie at term in a primigravida was taken up for Caesarean section, and a mature 8 pound live baby delivered from the abdominal cavity. The placenta was found adherent to the peritoneum.

Another was a case primary pelvic peritoneal pregnancy.

The third was a case of 14 week size foetus with the placenta adherent to the omentum.

The fourth was an incidental finding at laparotomy for a left ovarian cyst, when a mass 8 cm diameter was found adherent to the omentum. This mass contained a 3 cm foetus, necrotic material

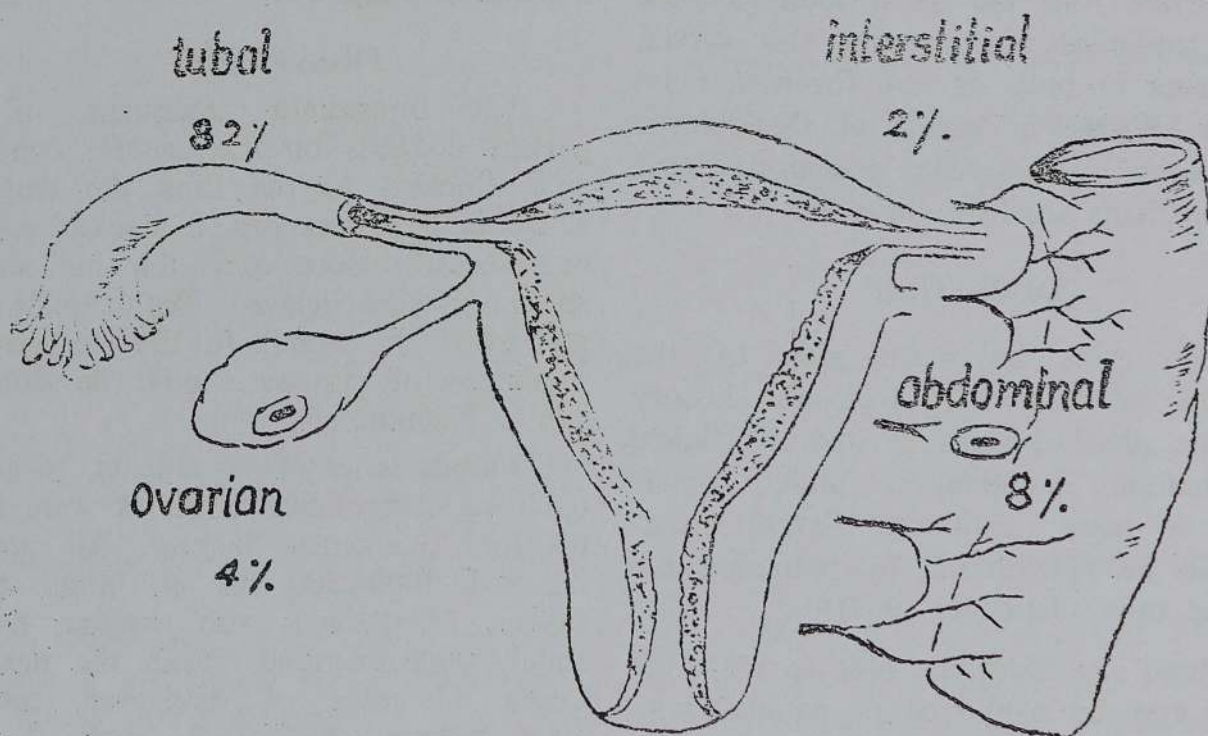


Fig:

Sites and incidence of ectopic pregnancy in this study.



**Table VI: Findings at Laperotomy in 48 Cases:  
Comparison with reported findings**

Site	Right side	Left side	Total No	Percentage	Reported <sup>1</sup> percentage in Literature
Tubal Pregnancy	25	16	41	82%	95 - 97%
Abdominal Pregnancy	—	—	4	8%	0.03%
Ovarian Pregnancy	1	1	2	4%	0.5%
Interstitial Pregnancy	—	1	1	2%	2 - 4%
Cervical Pregnancy	—	—	—	—	0.1%

<sup>1</sup> Figures from Te Linde's Operative Gynaecology: 5th Ed: p.369

and chorionic villi - consistent with that of an ectopic pregnancy.

In cases of abdominal pregnancy the foetus is removed, but placenta is left behind if its removal cannot be accomplished without haemorrhage; for removal at a later date (Thompson, 1966).<sup>16</sup>

Abdominal pregnancy is rare occurring once in 15,000-25,000 pregnancies and constitutes about 0.03%-0.5% of all ectopics. In this series its incidence is 8%.

#### Ovarian Pregnancy:

There were two instances of ovarian pregnancy in this series, both confirmed by histology.

In one there was a haemorrhagic ovarian mass which revealed a sac in which a 2.5 cm embryo was found. In the other case, microscopically-chorionic villi with decidual cells adjacent to the corpus luteum consistent with that of ovarian pregnancy was found.

Both cases were treated by oophorectomy.

Ovarian pregnancy is also rare, occurring 1 in 10,000-20,000 pregnancies and constitutes 0.5% of ectopics. In this series it accounted for 4%.

#### Interstitial Pregnancy:

There was a single case of interstitial pregnancy, with a 12 week size foetus contained in a sac situated on top of the left uterine cornu, unruptured. The sac was excised and uterine wall repaired.

The incidence of interstitial pregnancy in this series is 2%.

#### SUBSEQUENT PREGNANCY AFTER ECTOPIC GESTATION

It is important to appreciate that the occurrence of an ectopic pregnancy is not merely an isolated episode in a woman's life. It has very profound implications with regard to her reproductive performance. "She with only one tube has a 1 in 3 chance of ever producing a live child, but a 1 in 20 chance of having another ectopic pregnancy" (Grant 1962).<sup>8</sup>

#### CONCLUSION

The following conclusions are arrived at from this study.

1. The incidence of ectopic pregnancy in this series (0.19%) comes within the reported frequency range. (0.1-0.33%; Jeffcoate)



2. Present trends in fertility control may be influencing the frequency and mode of presentation of ectopic pregnancy.
3. In majority of the cases a diagnosis can be made with a carefully obtained history which is still the most important single aid to diagnosis. A diagnosis of ectopic pregnancy should never be excluded because the patient is having an IUCD or taking oral contraceptive.
4. The incidence of abdominal pregnancy (8%) and ovarian pregnancy (4%) in this study is very high compared to the reported figures.

## REFERENCES

1. BREEN, J. L. : Amer. J. Obs. Gynae. 106 : 1004 (1970)
2. BURKE, M; BUCK, P. : Brit. J. Hosp. Med. 15 : 552 (1976)
3. BRENNER, P. F. et al : Obs. / Gynae. 49 : 323 (1977)
4. HARRALSON et al : Amer J. Obs. Gynae. 115 : 995 (1973)
5. DOUGLAS, C. P. : British Medical Journal 11 : 838 (1963)
6. JEFFCOATE, T. N. A. : Principles of Gynae. 3rd Ed p. 264-281 (1967)
7. SANDMIRE, H. F., RANDALL, J. H. : Obs. Gynae. 14 : 227 (1959)
8. GRANT, A. : Clinical Obs. Gynae. 5 : 861 (1962)
9. HAYNES, D. M. : et al : Amer. J. Obs. Gynae 106 : 1044 (1970)
10. TIETZE, C. : Amer. J. Obs. Gynae. 96 : 1043 (1966)
11. BONNAR, J. : British Medical Journal 1 : 287 (1974)
12. HAWKINS, D. F. : British Medical Journal i : 387 (1974)
13. WYPER, J. F. B. : British Medical Journal i : 273 (1962)
14. KOBAYASHI, et al : Amer. J. Obs. Gynae. 103 : 1131 (1969)
15. BENDER, S. : J. Obs. Gynae. Brit. Empire, 63 : 400 (1956)
16. THOMPSON, L. R. : Amer. J. Surg. III : 272 (1966)



## FORENSIC ASPECTS OF DRUG DEPENDENCE

DR. N. SARAVANAPAVANANTHAN, M. B. B. S. (Cey.)

M. R. C. P. (U. K.) D. M. J. (Lond.)

*Judicial Medical Officer, Jaffna.*

Drug abuse in one form or another is as old as mankind, and it would seem that man is incapable of facing life without the aid of stimulants, sedatives and hallucinogens. For a long time the Chinese relied upon the opium pipe for relaxation and philosophic thoughts and the Peruvian labourer regarded his marihuana as a simple prop during the hot mid-day hours. An enthusiastic student takes amphetamine in order to keep awake. While L. S. D. and marihuana are expected to open up a new territory inside oneself. Dependence may cause both moral and physical degradation, sexual perversion and crime. It is in these respects that addiction may become a social menace. There is a threat to society not only from the drug dependents but also from those who traffic and peddle the drug. When does a Forensic pathologist see a drug dependent? He meets him when he is a victim of murder, accident and when he exhibits antisocial behaviour.

There is no doubt that many vested interests are involved in maintaining a pattern of drug abuse and when their position is threatened by a narcotic addict who knows too much he is got rid of quickly. A narcotic addict may be murdered by a 'hot shot'. This is a dose of narcotic with a poison such as strychnine in it. Death from a 'hot shot' at post mortem will show the findings of the particular adulterant. If the addict dies in the house of a narcotic 'pusher' his body is taken elsewhere and disposed of. Another method of homicide is the use of a purer blend than the addict has been

using. In other words the addict takes an over dose of the narcotic. The death from over dosage will show only the signs of anoxia and cerebral depression. Heroin is sometimes adulterated with quinine and some deaths will occur due to hypersensitivity to quinine. The quinine type deaths will show a beefy red congested lung. This has been described as 'heroin lung' but it is probably due to quinine.

There is a risk of suicide during the withdrawal phase of amphetamines. Two young boys<sup>1</sup> aged 18 years and 20 years who were known amphetamine takers, committed suicide by taking a large dose of methadone. Both methadone and amphetamine were detected in the urine, bile and tissues of the victims.

Among L. S. D. dependents delusions of omnipotence are common and they often think that they can fly from high buildings and a number of deaths have occurred in this manner. Death can also occur due to accidental overdosage, in morphine addicts. Autopsy findings are pin point pupils and those of anoxia. Bile should be collected because this is one of the very best places to look for this group of alkaloids.

Sometimes deaths among the dependents may mimic natural diseases. Unsterile syringes used by the addicts sometimes cause hepatitis, septicaemia etc. Ulcerative sub acute bacterial endocarditis with cerebral embolisation has been reported in heroin addicts. One should look carefully at the antecubital fossa and other injection sites like the arms and thighs. Due to the



material injected and the lack of antiseptics it is not unusual to notice scars in these areas. Fresh injection sites may appear as ecchymoses. Some may attempt to conceal the scar by tattooing the surrounding skin. Pulmonary arterial foreign body granuloma associated with angiomatids was reported by Butz<sup>2</sup> in relation to propoxyphene abuse. Tetanus is another cause of death in these cases. I had occasion to see two pethidine addicts die of tetanus. Sudden death may occur among L. S. D. and amphetamine addicts due to cardiac failure. According to Stevens<sup>3</sup> acute pulmonary drug reaction to intravenous barbiturate or opiate overdose is the main cause of death among drug addicts in the London area. Citron (1970)<sup>4</sup> reported a few cases of necrotizing angitis indistinguishable from periarteritis nodosa in methyl amphetamine users and these patients presented with systemic signs and symptoms of renal failure, hypertension and pancreatitis.

**Drugs & Driving:** Information about the effect of drugs on driving is extremely scant. Little or nothing is known about the correlation between driving skill and blood concentration of drugs.

Euphoria which cannabis is said to produce is associated with impairment of judgement and since it disturbs perception of space and time, driving while under its influence could be disastrous. Further in cannabis there is an impairment of memory for recent events and consequently driving of motor vehicles is impaired because the driver forgets essential things like looking at the speedometer to check speed.

Amphetamines are dangerous when taken indiscriminately. Large dose can impair coordination and driving skill. Moderately large doses of barbiturate can produce effects resembling alcoholic intoxication, like unsteady gait, slurred speech confusion etc., hence driving under its influence could be dangerous.

### Criminological aspects of drug dependence.

From a medico legal point of view dependence whether it be physiological or psychological can lead to anti social behaviour.

**Cannabis and crime:** (1) The individual addicted to cannabis is abnormally suggestible and can consequently be easily led into crime. Loss of control during cannabis intoxication may result in violence or other types of impulsive behaviour. (2) The lethargy induced by cannabis may lead to loss of earning capacity and therefore indulgence in petty thieving. (3) Cannabis may provide persons predisposed to criminality with the courage to commit anti-social acts. Many studies have shown that marihuana users committed petty crime and found no evidence that the practice was associated with major crimes. However, a case of homicide while in a state of intoxication resulting from smoking ganja occurred in Puttalam district in 1968.<sup>5</sup>

A young man shot his two little sisters aged 10 years and 11 years in the early hours of the morning while they were asleep and the prosecution could allege no motive for the act. According to the evidence the accused looked after his sisters and was fond of them. On the night of the incident he had taken a bottle of beer and some arrack and he had smoked ganja sometime after mid-night. Immediately after he fired the shot he is supposed to have said "I have shot" and again "have I shot", indicating that there was not full awareness. He seemed to have had some doubt whether he had done it or not and this is in keeping with a confused state. It was held that he was in a state of intoxication resulting from smoking of ganja and was incapable of forming a murderous intention to kill his two sisters whom he had loved. The charge of murder was reduced to culpable homicide not amounting to murder and



the accused was sentenced to 10 years rigorous imprisonment.

#### Amphetamine and crime:


The amphetamine addict is quite unable to earn his living in the community and will resort to lies or fraud to obtain further supplies. Stealing and murder have been associated with excessive amphetamine taking. The relationship between criminality and the taking of amphetamines depends mainly on the degree of habituation and social background of the individual. The ordinary housewife who takes one or two tablets a day may well be habituated to the drug, yet is in no danger of becoming a criminal. An adolescent boy with an unsatisfactory home background who mixes up with others who are dependents of the drug runs a big risk of turning into a criminal. Amphetamine taking may endanger the life of an innocent person. Power (1974)<sup>6</sup> reported a case where a man in his early twenties with a two year history of amphetamine dependence administered an injection of barbiturate to a baby belonging to his friend with whom he was lodging. He defended his behaviour by stating that the baby was crying and keeping the household awake. His defence was not entertained and he was found guilty.

Violent anti social behaviour may also occur with L. S. D.

*Conclusion:* Drug taking and trafficking has become a problem especially among children, therefore illicit drug taking should be made a punishable offence and it is also necessary to have rules so as to enable the police to require a person detected of possessing or taking drugs to give a sample of blood or urine for analysis.

#### REFERENCES :

1. CAMPS F. E. - (1969) Recent advances in Forensic Pathology. - 212.
2. BUTZ B. (1969) - Journal Forensic Science, 14, 317.
3. STEVENS - (1978) - Death of drug addicts in London 1970-74 Medicine, Science and Law. Vol. 18 - No. 2. 128 - 136.
4. CITRON B. - (1970) - New England Journal of Medicine 283, 1003.
5. NEW LAW REPORTS - Sri Lanka Vol. 72 - p. 57 - 59.
6. POWER D. J. - (1974) - Illicit drug taking - Medicine, Science and Law. Vol. 14, No. 4, 257.





# NEW ANTIBIOTICS — HOW AND WHY ?

D. CHANMUGAM, M. D. (Ceylon), F. R. C. P. (London)

*Department of Medicine, University of Colombo.*

Almost 50 years ago Alexander Fleming reported the discovery of a substance produced naturally by a micro-organism, a mould *Penicillium Crysogenum*, which killed other microorganisms. He called this substance Penicillin but was unable to produce enough of the pure substance to use it. It was left to H. W. Florey and E. B. Chain at Oxford to demonstrate in 1940 the clinical effectiveness of Penicillin. When its remarkable actions were confirmed many workers all over the world looked for similar natural substances and in 1942 S. W. Waksman in U. S. A. discovered Streptomycin and with its introduction there was a dramatic reduction in the mortality of Tuberculosis. It was then thought that the era of an infection free world had dawned, but this was not to be. Bacteria began to develop

In the ensuing 40 years over 3000 antibiotics have been discovered. But only about 60 of them are known to have the correct properties, namely high activity against the invading organisms, low toxicity and physical and metabolic stability, to enable it to be used. These 60 or so antibiotics belong to one of seven structural types shown in the table and no structurally new antibiotic has been discovered since the 1950s.

All important discoveries in the last 20 years either from a microbial origin or chemical alteration of existing antibiotic molecules belong to one of these seven classes.

The main impetus to the development of new antibiotics is the emergence of resistant strains. Within a few years

Year of Discovery	Class	First useful member
1940	Beta Lactam	Penicillin G
1944	Aminoglycoside	Streptomycin
1947	Chloramphenicol	Chloramphenicol
1948	Tetracycline	Tetracycline
1950	Macrolide	Erythromycin
1955	Lincomycin	Lincomycin
1957	Ansamacrolide	Rifampicin

TABLE: STRUCTURAL CLASSES OF THE MAIN ANTIBACTERIAL AGENTS

resistance to each antibiotic as it was introduced and so the search for new antibiotics goes on.

of the introduction of the synthetic antibacterial, sulphonamide in the 1930s, gonococci and some streptococci which had



dramatically succumbed to sulphonamides began to show resistance to the drug so that shortly the treatment by sulphonamides of the disorders caused by these organisms had to be abandoned. Fortunately Penicillin arrived on the scene by then. For many years the gonococcus was sensitive to small amounts of Penicillin in the blood stream but over the last few years the organism has required larger and larger doses of Penicillin for eradication and now completely resistant strains are emerging. Streptococci have been uniquely sensitive to Penicillin all over the world but even here in the past couple of years resistant strains are beginning to appear. But it was with staphylococci that the limitations of Penicillin G became specially noticeable for within a decade of its introduction as much as 50 percent of staphylococci isolated in hospitals were resistant.

Unlike human cells, bacterial cells have tough outer shells and penicillin is able to act selectively on these cells by interfering with their biosynthesis and without an action on the human host cell. The bacterial response was to elaborate an enzyme penicillinase which inactivated the penicillin molecule. Much research went into working out the structure of the penicillin molecule and in 1945 using X-ray crystallography Dorothy Hodgkin worked out the formula. It was then found that the antibacterial activity of penicillin resided solely in a four membered ring known as the Beta Lactam ring. Penicillinase destroyed a bond between nitrogen and a carbon monoxide group in this ring inactivating the molecule. Scientists in the pharmacological industry isolated the nucleus of the penicillin molecule and identified it as 6 - amino-penicillanic acid (6-APA), which itself has no antibacterial activity at all. They urged that if the N-CO bond of the beta lactam which was the target of the enzyme penicillinase

could be protected from the enzyme then the antibacterial activity could be maintained. This started the era of the synthetic penicillins of which methicillin was the first. Here two large methoxy groups attached to an amino group of the beta lactam ring protected the molecule from penicillinase enzyme and trials showed its efficacy against penicillinase producing staphylococci. While tinkering with the penicillin molecule scientists discovered that the nature of the organic acid of 6-APA affected the antibacterial activity of the molecule. From these researches came the 25 or so penicillins now available for clinical use.

Again from Oxford an antibiotic cephalosporin C was identified. This was the second antibiotic that contained the beta lactam group. From cephalosporin C a nucleus, 6 aminocephalosporonic acid similar to 6-APA was identified and from this other cephalosporins were synthesized. There is no cross resistance between the cephalosporins and the penicillins so that the two can be used together for their complementary actions.

**Aminoglycosides**—The next important step in the continuing war against resistant strains of bacteria was the discovery of the aminoglycosides of which streptomycin was the first. Later antibiotics of this group are gentamicin, kanamycin and tobramycin. All of them have the same serious disadvantage of being nephrotoxic and ototoxic, toxicity being dose dependent. Just like the penicillins and cephalosporins, the aminoglycosides too are inactivated by bacterial enzymes. Using the prior examples of synthetic penicillins, scientists have modified the chemical structure of aminoglycoside to protect it against these enzymes, producing synthetic aminoglycosides like amikacin.



Recently in a research laboratory searching for an effective substance against penicillinase of which there is not one but several, workers discovered from the products of fermentation a substance clavulanic acid which is a weak antibiotic of the beta lactam group but more importantly effectively inhibits the different penicillinases. When combined with a right penicillin, eg. amoxycillin and used

against penicillinase producing bacteria, the clavulanic acid neutralizes the penicillinase which would otherwise have inactivated amoxycillin.

Thus there are now several antibiotics which the clinician can use. Nevertheless the serious problem of new resistant bacteria remains necessitating continuous research into discovering new antibiotics.



## FOUR CHILDREN WITH OBSTRUCTIVE EMPHYSEMA

S. VYRAVANATHAN, M. B. B. S. (Ceylon), T. D. D. (Wales)

*Medical Officer in-Charge*

*Chest Clinic Kandy*

### Introduction

**O**bstructive emphysema or local obstructive emphysema is the term used to describe the distension of alveoli resulting from a check-valve type of obstruction of a large bronchus. It is one form of emphysema of the lung which has been clearly defined in terms of aetiology, clinical and radiological features and morbid anatomy. (Ogelvie 1963)<sup>1</sup>

This paper is a report on four children with this condition seen by the author over 14 years (1961-74) of chest clinic practice in Sri Lanka.

### Case Reports

Case 1: On 17th Nov., 1961 a 16 year old boy was referred to the Chest Clinic, Anuradhapura from District Hospital, Dambulla for investigation of suspected pneumothorax. The referred slip also contained the information that this boy has had a chest X'ray done at General Hospital, Kandy and that it was reported as "clear".

He complained of cough and shortness of breath of six weeks duration. On examination he had a paroxysmal cough. Movements were diminished, the percussion note resonant and breath sounds were decreased over the left side.

A chest X'ray revealed hypertransradiancy of the left lung fields with splayed out blood vessels (Fig. 1a) suggesting either compensatory or obstructive emphysema of the left lung. There was

no evidence of a collapsed lobe in the X'ray (P-A or left lateral) to account for a compensatory emphysema. A chest X'ray taken in full expiration (Fig. 1b) showed that in addition to the hypertransradiant left side there was also a marked shift of the trachea on to the right side, raised right leaf of the diaphragm and clouding of the right lung. All these features confirmed the suspicion of obstructive emphysema.

The boy was questioned regarding the inhalation of any foreign body to account for the obstructive emphysema. After prolonged questioning he recollected that while he was eating "dhamba" fruit more than six weeks earlier, a seed had "gone the wrong way". He had a slight cough at that time which he had soon forgot. A diagnosis of obstructive emphysema following inhalation of dhamba seed was made.

His white blood cell count was 23,400/- cu mm; of which the neutrophils were 80./., Lymphocytes 14./ and Eosinophils 6./. He was treated with Penicillin and referred to Mr. A. T. S. Paul, Thoracic Surgeon, Colombo who removed the seed at bronchoscopy. Following this the boy became symptom free and a repeat X'ray was normal.

Case 2: A 1 year and 8 months old boy was referred to Chest Clinic, Batticaloa on 5th June, 1967 from the General Hospital, Batticaloa for investigation of suspected pneumothorax. He had a cough and was short of breath for the past 8 days. On



examination the chest movements were decreased, the percussion note was hyper resonant and the breath sounds were decreased over the left side.

A chest X'ray (Fig. 2a) showed hypertransradiancy of the left lung fields with splayed out blood vessels suggesting either compensatory or obstructive emphysema. There was no evidence of a collapsed lobe either in the postero anterior or lateral X'ray to account for a compensatory emphysema. X'ray of the chest taken in full expiration (Fig. 2 b) showed in addition a marked shift of the heart and trachea to the right side, raised right leaf of the diaphragm and clouding of the right lung fields. All these features confirmed the suspicion of obstructive emphysema.

The boy's mother was questioned about the possibility of the boy having inhaled any foreign body. She recollected that the boy had picked up a piece of manioc and put it into his mouth a few days earlier and that it might have "gone the wrong way".

A diagnosis of obstructive emphysema following inhalation of a piece of a manioc was made; and preparations were made to transfer the child to the Thoracic Surgeon in Colombo. But 3 days later the boy coughed up the piece of manioc and cured himself.

Case 3: An 8 year old boy from Deltota was seen at Chest Clinic, Kandy on 15th Sept., 1973. He had a cough of 2 weeks duration. On examination the percussion note was hyper-resonant and the breath sounds were diminished on the left side. Rhonchi and crepitations were heard on both sides.

A X'ray of chest (Fig. 3) showed enlargement of mediastinal and hilar nodes more marked on the left side, hypertransradiancy of the left lung with splayed out the blood vessels. There was no evidence of a collapsed lobe in the X'

ray to suggest compensatory emphysema as the cause of the hypertransradiancy. The cause of the hypertransradiancy was obstructive emphysema. The X'ray of the chest done in full expiration did not show a shift of the heart or trachea to the — right side. The Mantoux test was positive (18 mm).

A diagnosis of "primary tuberculosis with enlarged mediastinal and hilar lymph nodes and left sided obstructive emphysema" was made.

As the parents wished to have the boy treated at Deltota, arrangements were made to treat him with Streptomycin and isoniazid twice weekly for 2 years at District Hospital, Deltota. A X'ray of the chest taken about 8 months later now showed collapse of the left upper lobe. A further X'ray taken in August 1975 after nearly two years of anti tuberculous therapy showed no enlarged mediastinal and hilar nodes and no abnormality in the lung fields.

Case 4: A 1 year and 4 month old boy was seen at the chest clinic Kandy on 7th June 1974 with cough and noisy breathing of 6 months duration. The mother had noticed that the cough started after the child had inhaled an artificial pearl and that the cough came in bouts.

On examination, movements were diminished, the percussion note was resonant and the breath sounds were decreased over the left side of the chest.

Hypertransradiant lung fields with splayed out blood vessels suggesting either obstructive or compensatory emphysema was seen on the left side of a X'ray of chest. There was no evidence of collapse of a lobe in the postero-anterior or lateral X'ray to suggest compensatory emphysema. A X'ray of the chest taken in full expiration showed a shift of the trachea but not of the heart to the right. A diagnosis of obstructive emphysema



resulting from inhalation of an artificial pearl was made.

At bronchoscopy the Surgeon (Dr. H. S. Perera, Thoracic Surgeon) visualized the artificial pearl but could not remove it as it was slippery. During the attempt at removal the pearl was pushed down the lower lobe orifice. A X-ray of the chest taken soon after that (on 6th Sept. 74) showed no evidence of obstructive emphysema but it showed evidence of collapse of lateral basal segment of the left lower lobe.

At a second bronchoscopy the pearl was removed and the child was symptom-free after that. The child was given Penicillin before and after bronchoscopy.

## DISCUSSION

**MECHANISM OF PRODUCTION:** The mechanism of production of this condition was described by Jackson and Jackson (1936).<sup>2</sup> When there is a check valve type of obstruction of a bronchus the air enters the lung beyond the obstruction as the bronchus widens during inspiration but does not leave that part of the lung as the bronchus narrows during expiration. A great pressure thus builds up behind the obstruction leading to dilatation emphysema of the panacinar type (Ogelvie 1963)<sup>1</sup>.

**CAUSES:** The causes of obstructive emphysema in these children were foreign bodies in three of them and tuberculous lymph node in one. Two of the foreign bodies were vegetable foreign bodies (dhamba seed in case 1 and piece of manioc in case 2); the third was a non-vegetable foreign body (artificial pearl in case 4).

**INCIDENCE:** An incidence of only 4 cases of obstructive emphysema over a 14 year period of chest clinic practice suggests that obstructive emphysema is an uncommon condition. This is in conformity with other reports, Botha (1958)<sup>3</sup>

refers to only 5 instances among 35 cases with proven inhaled foreign bodies admitted to hospital over a period of 12 years. Davies (1961)<sup>4</sup> found only 2 instances of obstructive emphysema due to primary tuberculous lymph nodes among contacts studied from 1930 to 1952. Crofton and Douglas (1975)<sup>5</sup> state that obstructive emphysema due to primary tuberculous lymph nodes is rare in most series. Closer home, de Silva (1974)<sup>6</sup> reporting on 12 children with intrabronchial foreign body admitted to hospital during the year 1973/74, found no case of obstructive emphysema.

That this low incidence of obstructive emphysema may be more apparent than real will be explained later on in this paper.

**AGE DISTRIBUTION:** It is noteworthy that two of the three children were in the 1 to 2 year group, an age when children tend to introduce foreign bodies into their mouths. De Weese and Saunders (1968)<sup>7</sup> state that most foreign bodies in the bronchi occur in children who suddenly inspire when they have foreign bodies in their mouths.

Case 3 with tuberculous lymphadenitis was 8 years old. According to Miller et al (1963)<sup>8</sup> obstructive emphysema due to primary tuberculous lymph nodes is commoner in children under the age of two years.

**SIDE INVOLVED:** Wilson (1962)<sup>9</sup> states that foreign bodies are more likely to find their way to the right side as the right main bronchus is larger than the left and more in line with the trachea. But in the three cases described here the foreign bodies were lodged in the left bronchus. In case 3 the obstructive emphysema due to primary tuberculous lymph node occurred on the left side. In the two cases described by the Davies (1961)<sup>4</sup> one had it on the right side the other on the left side.



**SYMPTOMS:** These patients present with cough which may be paroxysmal and shortness of breath or noisy breathing. When these symptoms follow inhalation of a foreign body, the history of inhalation may be readily forthcoming as in case 4, or it may have to be elicited by prolonged questioning as in cases 1 and 2.

**PHYSICAL SIGNS:** The physical signs in the chest are: resonant or hyper-resonant percussion note with diminished breath sounds. Other conditions which can present with the same physical signs are: spontaneous pneumothorax, compensatory emphysema, infantile lobar emphysema, unilateral emphysema of lung (Macleod's Syndrome), congenital cystic (adenomatoid) malformation of the lung and diaphragmatic hernia.

**RADIOLOGICAL FEATURES:** The radiological changes occurring in obstructive emphysema were described in detail by Rabin (1952).<sup>10</sup> It is the usual practice to take X-rays of the chest in full inspiration. The changes of obstructive emphysema seen in this phase of respiration are hypertransradiancy and splaying out of the blood vessels on the affected side. Sometimes the affected side may appear very much like the normal side. And unless this condition is suspected and particularly looked for it may be missed even by experts. This may be one of the reasons for the reported low incidence of obstructive emphysema.

The additional changes which are seen in the expiratory film depend on whether the lower lobe bronchus or the upper lobe bronchus is mainly affected by the valvular obstruction. If the lower lobe bronchus is mainly affected there is shifting of the heart to the opposite side, the leaf of the diaphragm on the opposite side rises and there is normal clouding of the lung on the opposite side with deflation. In cases 1 and 2 these

changes were noticeable in the expiratory films probably because the lower lobe bronchus was the main site of valvular obstruction.

In cases 3 and 4 there was no shift of the heart to the opposite side in the expiratory films. So that obstructive emphysema in these two cases was due to valvular obstruction not of the lower lobe bronchus but of the upper lobe bronchus. And the shift due to distension of the upper lobe would be expected in the upper mediastinum. According to Rabin (1952)<sup>10</sup> the shift of the heart due to valvular obstruction in the lower lobe is often well seen in X-rays but the shift of the upper mediastinum i. e. shift of the trachea to the opposite side by a distended upper lobe is not often seen in X-rays, though it may be noticeable on screening. Expiratory film in case 4 showed a shifting of the trachea to the right, suggesting involvement of the left upper lobe bronchus. The expiratory film in case 3 did not show a obvious shift of the trachea to the side opposite to that of the lesion, but a follow up X-ray (taken months later) showed collapse of the left upper lobe suggesting involvement of the left upper lobe bronchus.

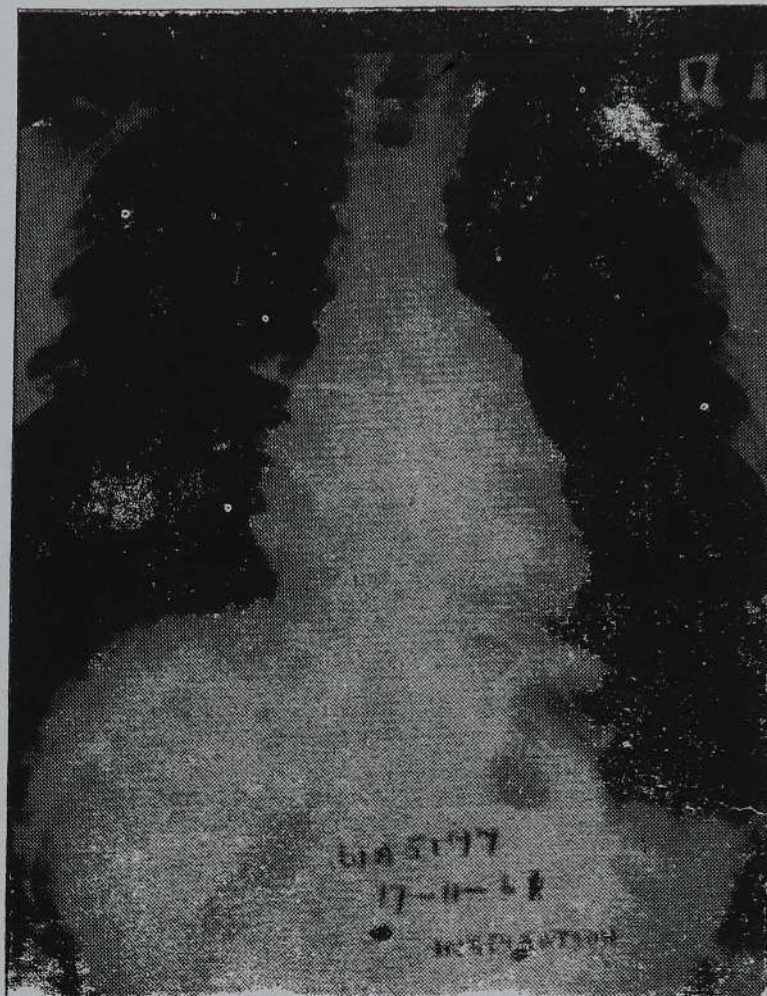
In children, particularly, the standard film may be taken at mid-inspiration or even at expiration, so that the side to which the heart is shifted may be erroneously assumed to be the side of collapse and the obstructive emphysema on the other side completely missed. This may be yet another reason for the reported low incidence of obstructive emphysema.

**OTHER CONDITIONS CAUSING HYPERTRANSRADIANCY:** The other conditions which simulate obstructive emphysema clinically also present a picture of unilateral hypertransradiancy in the X-ray, occasionally making differentiation difficult. Spontaneous pneumothorax can be recognized by the lung border seen

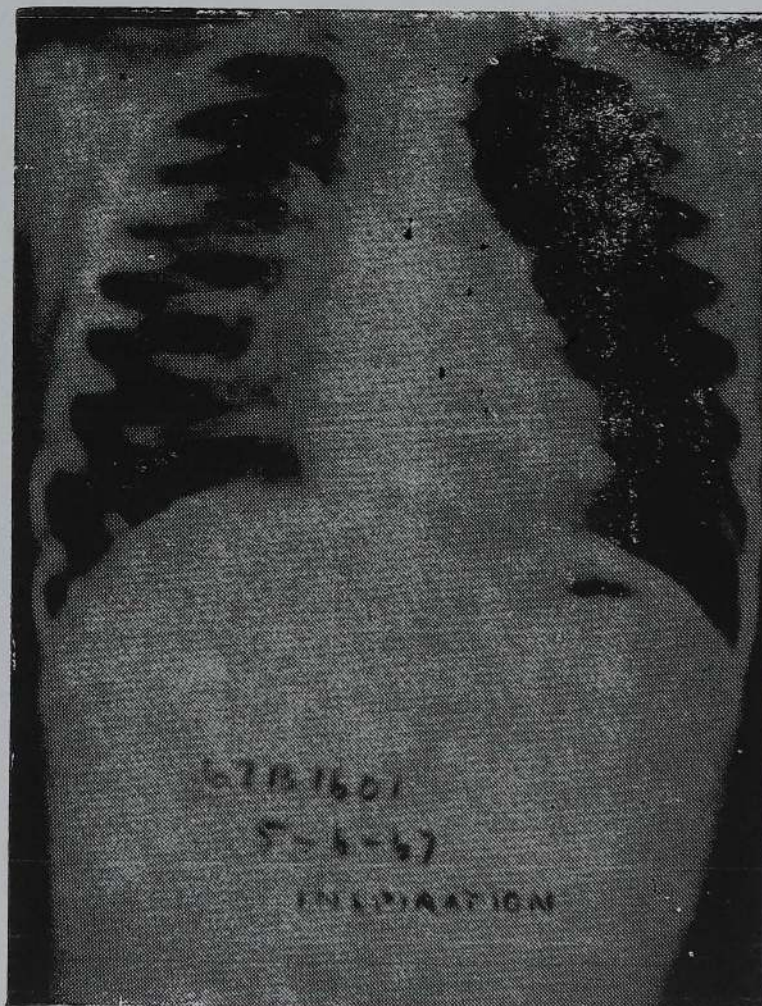






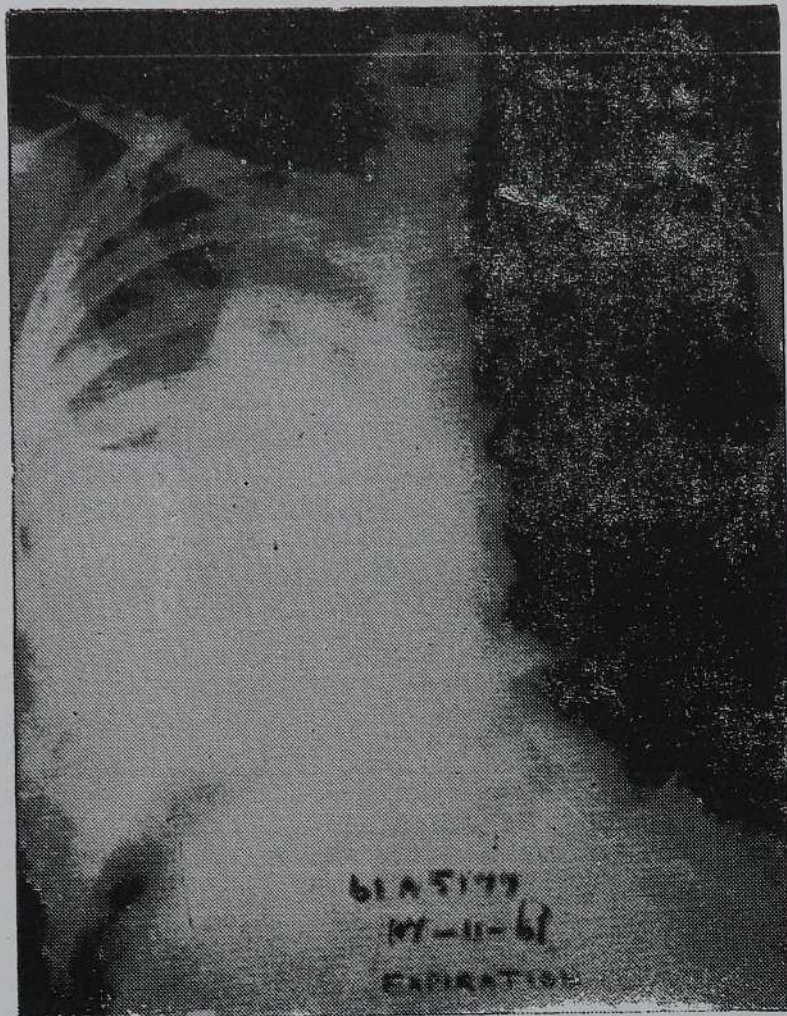


**Fig. 1 a - Case 1:** Chest X'ray showing hypertransradiancy left side.

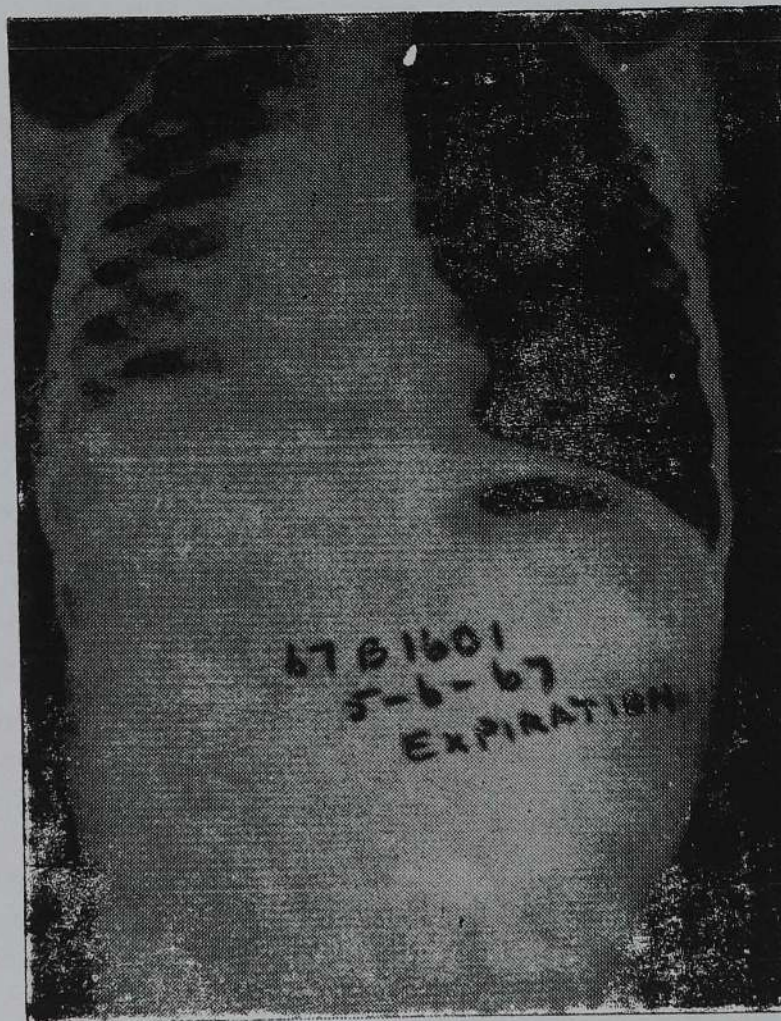


**Fig. 2 a - Case 2:** Chest X'ray showing hypertransradiancy left side.



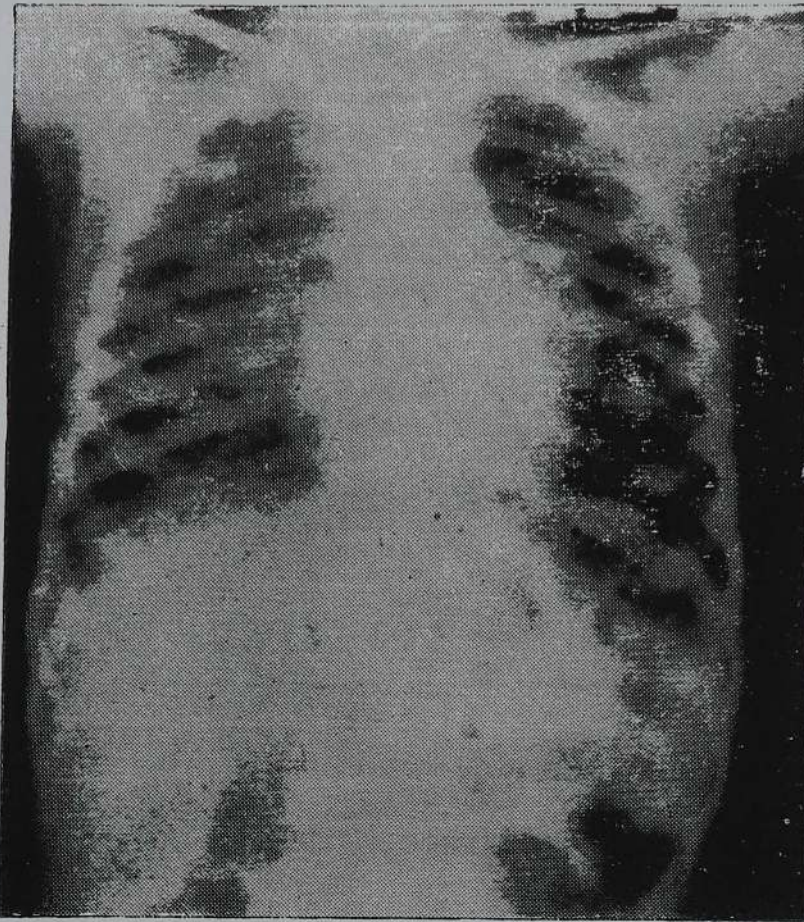

**Fig. 1 b - Case 1:** Expiratory film showing hypertransradiancy left side and shift of the heart and trachea to the right.

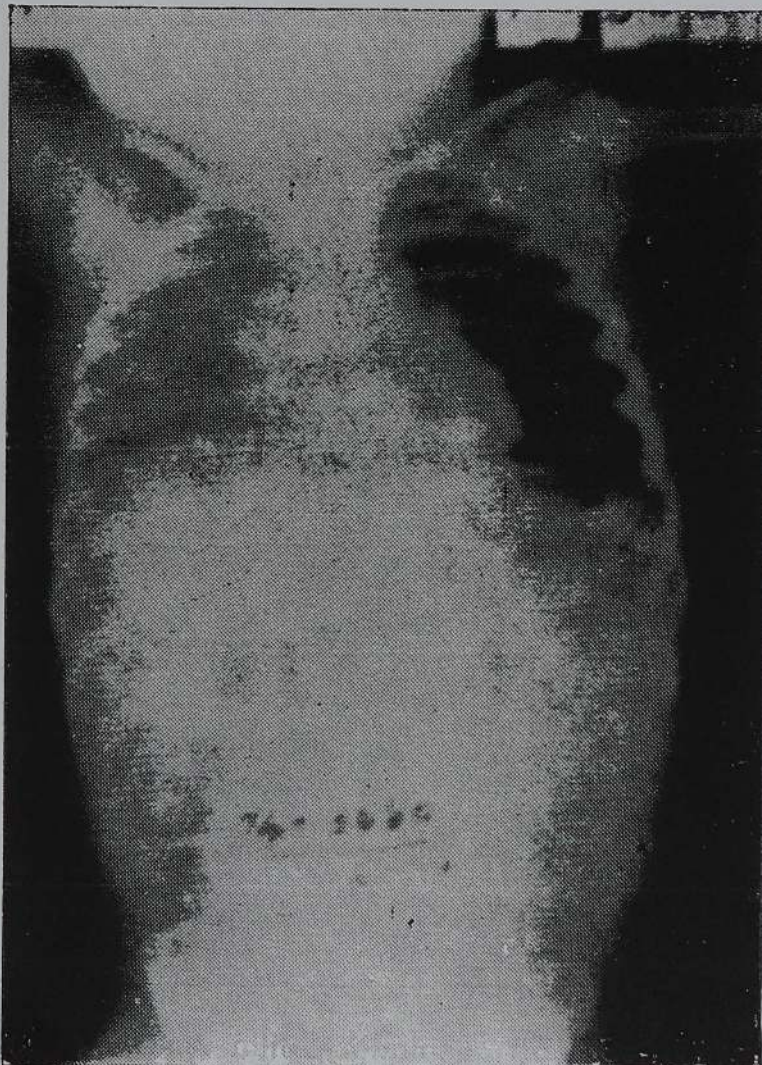


**Fig. 2 b - Case 2:** Expiratory film showing hypertransradiancy left side and shift of the heart and trachea to the right.





**Fig. 3 - Case 3:** Chest X'ray hypertransradiancy left side and enlargement of mediastinal and hilar lymph nodes (more marked on the left side).



**Fig. 4 - Case 4:** Chest X'ray showing hypertransradiancy.



medial to the area of transradiancy. In the case of compensatory emphysema, the collapse which gives rise to it can be seen as a lobar shadow, better seen in the lateral film. Infantile lobar emphysema which occurs in the newborn is seen as an area of transradiancy compressing the rest of the lung. Macleod's Syndrome may be difficult to differentiate radiologically but the absence of symptoms and decrease in the shadows of the blood vessels both at the hilum and the rest of the lung should suggest the diagnosis (Crofton & Douglas 1975)<sup>5</sup> which can be confirmed by angiography. In congenital cystic adamantoid malformation, most cases present with a predominantly cystic appearance in the X'ray; some may show a rather solid appearance (Moncrief et al 1969).<sup>11</sup> Diaphragmatic hernia is easy to recognise radiologically by the presence of coils of intestine in the chest. Clinically bowel sounds may be heard in the chest. X'ray after barium meal may be necessary to confirm diagnosis.

**FURTHER PROGRESS OF VALVULAR OBSTRUCTION:** After sometime a vegetable foreign body in the bronchus begins to swell (Wilson 1962).<sup>9</sup> In the bronchial wall there is a reaction which comes on more rapidly with a vegetable foreign body than with a non-vegetable foreign body. These changes may at times enhance the efficacy of the check-valve mechanism leading even to rupture of alveoli with leak of air into the interstitial tissue. From there the air may find its way into the mediastinum and to the subcutaneous tissue in the neck (Botha 1958).<sup>3</sup> None of the four cases reported here developed this complication.

Sooner or later the check-valve type of obstruction is converted to a complete obstruction in inspiration as well as expiration. The air distal to the obstruction gets absorbed with resultant collapse of that portion of the lung. The time

taken for this conversion may be anything from a few minutes to several weeks after inhalation, the average being six days (Botha 1958)<sup>3</sup>. In case 4 during the first attempt at bronchoscopic removal the artificial pearl was pushed down the lower lobe bronchus with resulting collapse of the lateral basal segment of the left lower lobe. A tuberculous lymph node, by further pressure or more likely, by further erosion converts a check-valve type of obstruction to a complete one as occurred in the follow up X'ray in case 3 which showed collapse of the left upper lobe. From the foregoing account it becomes clear that obstructive emphysema is often a transient phenomenon. It is quite possible that a large number of cases of bronchial obstruction are X'rayed either before the development of obstructive emphysema or after the occurrence of complete obstruction and collapse of the lung. This may be yet another reason for the reported low incidence of obstructive emphysema.

In cases 1 and 4 the obstructive emphysema was seen six weeks and six months respectively after inhalation of the foreign body. In case 4 the artificial pearl being a smooth, slippery, non-vegetable foreign body could be expected to be bobbing up and down for that length of time even though the duration was too long. But the presence of obstructive emphysema six weeks after inhalation of a vegetable foreign body like dhamba seed is unusual.

**TREATMENT:** Treatment of obstructive emphysema caused by foreign bodies is by bronchoscopy and removal of the foreign body. Antibiotics should be given if there is infection.

When obstructive emphysema is caused by primary tuberculous lymph node, anti-tuberculous chemotherapy is the mainstay of treatment. Bronchoscopy is unnecessary in most cases. Corticosteroid



drugs may be useful to relieve the valve action (Crofton and Douglas 1975).<sup>5</sup>

**OUTLOOK:** All foreign bodies must be removed by bronchoscopy. If removal is not effected the valvular obstruction becomes complete leading to collapse, infection, lung abscess and bronchiectasis (Linton 1957).<sup>12</sup>

It is unusual for a child to cough up the foreign body as did case 2. It has been found that coughing up of foreign bodies occurred only in 2 per cent of cases (Thomson and Negus 1948).<sup>13</sup> In obstructive emphysema due to tuberculous lymph nodes the condition resolves with chemotherapy without important residual damage (Crofton and Douglas 1975).<sup>5</sup>

### SUMMARY

Four cases of obstructive emphysema in children are reported. Three were due to intrabronchial foreign bodies two of which were removed at bronchoscopy and the third was "coughed up". The fourth case due to primary tuberculous lymph node was cured with antituberculosis chemotherapy. The incidence, pathogenesis clinical and radiological features, differential diagnosis and complications of this condition are discussed.

### REFERENCES:

1. OGELVIE C. (1963) Emphysema of the Lung in *CHEST DISEASES* Vol. ii edited by K. M. A. Persy and Sir Thomas Holmes Sellors, London, Butterworths.
2. JACKSON, C and JACKSON, C. E. (1936) *DISEASES OF THE AIR AND FOOD PASSAGES OF FOREIGN BODY ORIGIN* W. B. Saunders, Philadelphia.
3. BOTHA, G. S. M. (1958) Obstructive emphysema due to Chronic inhaled foreign body in the bronchus. *Brit J. Tuberc.* 52, 134.
4. DAVIES, P. D. B. (1961) The Natural history of Tuberculosis in children. *Tubercle* London Vol. 42, March Supplement Page 26.
5. CROFTON, J. and DOUGLAS, A. (1975) *RESPIRATORY DISEASES* Blackwell Scientific Publications, Edinburgh.
6. DE SILVA, S. (1974) Intrabronchial Foreign bodies in children. *Ceylon Medical Journal* Vol. 19 page 154.
7. DE WEESE, D. D. and SAUNDERS W. H. (1968) *TEXT BOOK OF OTOLARYNGOLOGY* The C. V. Mosby Company, St. Louis.
8. MILLER, F. J. W., SEAL, R. M. E. TAYLOR MARY, D., PROBERT, W. R. and THOMAS, D. M. E. (1963) *TUBERCULOSIS IN CHILDREN*, London, Churchill.
9. WILSON T. G. (1962) *DISEASES OF EAR, NOSE and THROAT IN CHILDREN* William Heinemann Medical Books Ltd. LONDON.
10. RABIN, C. B. (1952) *XRAY DIAGNOSIS OF CHEST DISEASES* The Williams & Wilkins Co. Baltimore.
11. MONCRIEFF, M. W. CAMERON A. H. ASTLEY, R., ROBERTS, K. D., ABRAMS, L. D., and MANN J. R. (1969). Congenital Cystic Adenomatoid malformation of the lung. *Thorax*, 24, 476.
12. LINTON, J. S. A. (1957). Long-standing intrabronchial foreign bodies. *Thorax*, 12, 164.
13. THOMSON ST CLAIR AND NEGUS, V. E. (1948) *DISEASES OF THE NOSE AND THROAT* Cassell, London,



# COOMBS—POSITIVE HAEMOLYTIC ANAEMIA AND THROMBOCYTOPENIA ASSOCIATED WITH HODGKIN'S DISEASE

N. NAGARATNAM, R. G. RAJARATNAM, G. AMBEPITIYA,  
AND H. S. R. WIJEMANNE  
*General Hospital, Colombo.*

**SUMMARY:** A 52 year old female with Hodgkin's disease manifested initially immune haematological disorders. She had severe Coombs positive auto-immune haemolytic anaemia and thrombocytopenia which responded well to corticosteroid therapy. Four months later she developed Hodgkin's disease. Coombs test remained positive till her death 12 months later. Only 5 cases of Coombs positive haemolytic anaemia antedating Hodgkin's disease had been reported in literature.

**INTRODUCTION:** Coombs-positive haemolytic anaemia is a very unusual event in Hodgkin's disease. Eisner et al (1967)<sup>1</sup> in a study of 219 patients with Hodgkin's disease found 6 who gave a positive result to Coombs test. In none of them did the discovery of a positive Coombs test or overt haemolysis antedate the diagnosis of lymphoma. According to Cazenave et al (1973)<sup>2</sup> only 12 cases including one of their own have been reported in literature. In only 5 was its auto-immune nature proved by a positive direct Coombs test.

An auto-immune thrombocytopenia is still rarer phenomenon in Hodgkin's disease. In Harrington's (1956)<sup>3</sup> extensive studies he did not find a single case.

Herein we describe a 52 year old female who first presented with a Coombs positive haemolytic anaemia and thrombocytopenia and 4 months later was found to suffer from Hodgkin's disease. The

direct Coombs test remained positive till her death.

**CASE REPORT:** NVH (58243) a 52 year old married woman was admitted on 9th December 1972 with a history of burning epigastric pain and low grade fever of 4-6 days duration. On the day prior to her admission she noticed that her urine was darker than usual. Besides salicylates, she took no medication for her illness. Her past history included myomectomy and appendicectomy in 1966 and excision of a duct papilloma of the breast in 1968. She was never jaundiced.

Examination revealed an extremely pale and febrile (100°F) patient in severe pain. Sclerae were lemon yellow and the tongue coated. The lymph nodes were not palpable. Pulse was 80 per minute and regular. Blood pressure 130/70 mm. Hg. The heart was not clinically enlarged and a systolic murmur (Grade 2/6) heard over the praecordium. The lungs were clear. The spleen was just palpable.

The results of the investigations soon after admission were: Haemoglobin 3.5g/100 ml., reticulocytes 12% serum bilirubin 2.3 mg/100ml. WBC 17,400/mm,<sup>3</sup> neutrophils 82% and lymphocytes 18%. The blood picture revealed macrocytosis with a large number of polychromatic cells, a few spherocytes and pseudo--autoagglutination of red cells. Few nucleated red cells were present. There was an increase in the neutrophils with a shift to the left with a few myelocytes and



metamyelocytes. Direct Coombs test was positive while indirect Coombs was negative. SGPT was 60 I.U. Prothrombin time 23 seconds (control—17 seconds) Serum alkaline phosphatase 10 KA units. The rest of the liver function tests were normal. Urine: urobilin<sup>+++</sup>. Rheumatoid factor and anti-nuclear factor were negative. Doneth-Landsteiner test was negative. Agglutinins (cold and warm) were negative. LE cell preparation was negative. Platelet count on 14th December 1972 68,000/mm.<sup>3</sup>

A blood transfusion (2 pints) was given on 11th December 1972 with no untoward reaction. Corticosteroids (Prednisolone) 45 mg. daily was started on the same day and gradually reduced to 10 mg. daily. She became afebrile within 5 days of admission and remained so except for a bout of fever at the end of December when the dose of steroid was reduced. Reduction of the steroids brought on a haemolytic crisis, necessitating a blood transfusion. She was discharged after 42 days of stay in hospital on Corticosteroids (prednisolone) 20 mg. daily. She was still jaundiced slightly and her spleen was just palpable below the left costal margin. The Coombs reaction was persistently positive. On one of her visits to the Out-patients clinic 2½ months later two tender enlarged lymph nodes were noticed in the neck. A biopsy revealed Hodgkin's lymphoma. Splenectomy was performed on 2nd April 1973. The spleen was found to be enlarged with evidence of perisplenitis. Her post-operative period was uneventful except for fever which lasted for 12 days. The spleen on histology showed congestion of the pulp with marked areas of haemorrhages, fibrosis, marked reticulo-endothelial hyperplasia and Gandy-gamma Hodgkin's tissue.

She was treated with nitrogen mustard, vincristine, prednisolone and maintained on chlorambucil. Coombs test was positive till her death 12 months later.

**DISCUSSION:** The patient initially presented with an auto-immune haemolytic anaemia as evidenced by a positive Coombs test and reticulocytosis. Soon after in her clinical course she was thought to have a reticulosis a diagnosis supported by lymph node biopsy and later splenectomy. Coombs positive haemolytic anaemia is relatively an uncommon event in Hodgkin's disease. It was observed in only 2.7% of the patients with Hodgkins disease studied at the Memorial Hospital in New York. It may appear long before the disease manifest itself, the interval ranging from 2-26 months.

There is no doubt that the underlying disease caused the positivity of the Coombs test from the very beginning. Alternatively a positive Coombs test could arise following a blood transfusion. Fayen and Miale (1963)<sup>4</sup> reported that a false positive Coombs test could occur in patients with reticulocytes above 10%. This according to Giltman et al., (1965)<sup>5</sup> is due to the binding of the antibody contained in some Coombs sera to transferrin on the surface of the reticulocytes.

The haemolytic aspect of the disease in this present instance disappeared either concomitantly with or as the result of therapy received, although the Coombs test remained positive. This is known to occur occasionally and is well known for auto-antibodies, especially incomplete anti-erythrocyte auto-antibodies to undergo changes from one to the other variant or change in the degree of potency in a single patient during the course of the illness or as the result of treatment. Although it had been difficult to assess the significance of the positivity Coombs test to prognosis, Eisner et al., (1967)<sup>1</sup> noted a prolonged survival in their small number of positive cases.

In 9% of Hodgkin's disease the platelets are usually normal or increased at the beginning of the illness. More recently



it had been shown that in the generalised stage of the disease, production as well as survival of the platelets were reduced thus explaining the thrombocytopenia which may occur even in the absence of treatment. (Ultman and Movat, 1973),<sup>6</sup> Auto-antibodies may develop against the red cell, white cell, platelets or their precursors in the bone marrow. The development of auto-antibodies against the platelets may lead to an auto-immune thrombocytopenia which is a pathological analogue of auto-immune haemolytic anaemia.

In most auto-immune diseases of the blood the pathological mechanism is fairly well understood and this is particularly true of the auto-immune haemolytic disorders. It has been thought for some time that there may be an aetiological relationship between immune disease and malignant disease. Pirofsky (1965)<sup>7</sup> in an analysis of 234 cases of auto-immune haemolytic anaemia found 114 with neoplasia of the reticulo-endothelium. In 61.4% the neoplasia preceded the auto-immune haemolytic anaemia and in 7% was vice versa. This variation in whether the auto-immune haemolytic anaemia or the lymphoma appears first suggest that the two may actually appear independently of one another, each as a result of some underlying defect in the host, the patient being susceptible to both malignant lymphoma and immune disease. In NZB mice that recover from Coombs positive haemolytic anaemia the rate of malignancy is high Mellors et al (1966).<sup>8</sup> Still others Ziff et al (1961),<sup>9</sup> Fialkow et al (1964)<sup>10</sup> and Burnet et al (1963)<sup>11</sup> have stressed that the basic defect of the immune apparatus with impairment of the ability to have normal immune responses may occur through genetically mediated processes. Another theory is that repeated stimulation of the apparatus immunologically could lead to neoplasia of the reticulo-endothelium Clemick (1967).<sup>12</sup>

Fundenberg et al (1961)<sup>13</sup> encountered a patient who after a long standing 'adult' onset hypo-globulinaemia developed Coombs positive haemolytic anaemia and subsequently lymphoma. They postulated that, immune deficiency was the primary event in the predisposition to auto-immune diseases and lymphoma.

**ACKNOWLEDGEMENTS:** We wish to thank the Medical Superintendent, General Hospital for permission to publish this paper and the National Service Council of Sri Lanka for the grant No. 2/RG/73/15 to one of us (N.N.).

#### REFERENCES

1. EISNER, E., LEY, A. B. and MEYER, K. : Coombs positive hemolytic anaemia in Hodgkin's disease. *Ann. Intern. Med.* 66 : 258 (1967)
2. CAZENAVE, JEAN-PIERRE, GB-GON, J. A. E. GIROUARD, E. and BASTARACHE, A. Auto-immune haemolytic anaemia terminating seven years later in Hodgkin's disease. *Canad. Med. Assn.* 109 : 748 (1973).
3. HARRINGTON, W. J., MINNICH H., and ARINURA, G. — The auto-immune thrombocytopenia, *Progress in Haematology* Vol. 1 Tocantins, L. ed. New York, Grune & Stratton 166 (1956)
4. FAYEN, A. W. and MIALE, J. B. False positive antiglobulin tests in reticulocytosis, comparison of the tube and slide methods *Techn. Bull. Regist. Med. Techn.* 33 : 75 (1963).
5. GILTINAM, P. J., NORINS, L. C. and HOLMES, M. C. Relation of reticulocytes to positive Coombs tests in NZB and other mice. *Blood* 261 : 790 (1965)



6. ULTMAN, J. E. and MOVAN, E. M., Clinical course and complications of Hodgkin's disease Arch. Int. Med. 131 : 332 (1973)
7. PIROFSKY, B. Auto-immune haemolytic anaemia and neoplasia of the reticulo-endothelium with hypothesis concerning relationships. Ann. Int. Med. 68 : 109 (1965)
8. MELLORS, R. C. Auto-immune disease in NZB/B mice. 11. Auto-immunity an Malignant Lymphoma. Blood 27 : 435 (1966)
9. ZIFF, M., Genetic hypersensitivity and the connective tissue diseases. Amer. J. Med 30 : 1 (1961).
10. FIALKOW, P. J., FUDENBERG, K. and EPSTEIN, W. V. Acquired antibody haemolytic anaemia and familial aberrations in gamma globulins Amer. J. Med. 36 : 188 (1964)
11. BURNET, F. M. Theories of immunity, in Conceptional Advances in Immunology and Oncology New York, Harper & Row publisher Inc. p. 7 (1963).
12. OLEIMICK, A. : Leukaemia on lymphoma occurring subsequent to an auto-immune disease. Blood 29 : 144 (1967).
13. FUDENBERG, H. and SOLOMON A : Acquired agammaglobulinaemia with auto-immune haemolytic disease. graftversus host reaction. Vox Sang, 6 : 68 (1961).



## NEISSERIA MENINGOCOCUS INFECTIVE ENDOCARDITIS — A CASE REPORT

D. CHANMUGAM, M. D. (Ceylon), F. R. C. P. (London)  
RUKMAL WIJEDORU, M. B. B. S.

*Department of Medicine, University of Colombo.*

Over the years the disease infective endocarditis, continues to challenge and interest clinicians. Until the dawn of the antibiotic era the disease was termed bacterial endocarditis and sub divided - clinically into acute and sub acute forms mostly on the duration of the illness. This was largely an academic point as the disease terminated fatally in either variety. However since 1935 with the introduction of sulphonamides and later penicillin the distinction between acute and sub acute forms has become blurred and there is no advantage in trying to distinguish between acute and subacute forms so that these prefixes have now been dropped. Further while previously the infecting organism was always bacterial, today, the disease has been shown to be caused by Coxiella, Viruses, Chlamydia and even Fungi and the term bacterial has been replaced by infective. In addition newer clinical presentations have resulted from the wider use of prolonged intravenous infusions e.g. total parenteral alimentation (and also abuse by heroin and other drug addicts who have been known to use lavatory bowl water as a diluent for their intravenous injections), extensive cardiac surgery including prosthetic valve surgery, use of immuno suppressive and cytotoxic drugs in malignant disease and in transplantation patients. This has also extended the range of patients who develop endocarditis. As a result there has been a change in the

aetiology and prognosis of infective endocarditis over the last few years.

Whereas the disease was limited to infection of a valve or of a septal defect, today the condition includes infection of a prosthetic valve, mural endocardium, co-arctation of the aorta or an arterio-venous shunt.

We report a case of infective endocarditis which is unusual in two respects. Firstly the infecting organism was *Neisseria meningococcus*, an organism that has disappeared from the contemporary medical scene as an aetiological agent in this disease and secondly the cardiac lesion was an atrial septal defect which has been very rarely reported.

### Case Report

Mrs. GS, a 50 year old housewife was admitted with a presenting complaint of fever of 7 days duration. Six years previously she had been seen complaining of dyspnoea and tiredness. At that time a diagnosis of atrial septal defect probably of the ostium secundum type without significant pulmonary hypertension was made on the following features:- a left parasternal lift, loud systolic ejection murmur in the second left interspace, a widely split second heart sound in the pulmonary area with no variation in the degree of splitting with respiration, rSr' pattern in the right precordial leads of the ECG and in the chest X'ray mild cardiomegaly with a dilated pulmonary



artery and increased pulmonary vascularity extending to the periphery of the lung fields. The patient refused further investigations and was seen infrequently in the clinic. On examination the cardiac signs were unchanged. She was febrile, moderately pale and the spleen was easily palpable 2cms below the left costal margin. Her WBC was 16,000/mm<sup>3</sup> with 93% neutrophils. Other investigations included serum bilirubin 1.4 mg/100 ml, haemoglobin 8.7 grams/100ml, ESR 65 mm, SGOT 15 iu/ml, SGPT 7 i. u/ml, urine analysis was normal and the S.A.T. was negative. A provisional diagnosis of infective endocarditis was made and two blood cultures were taken after which the patient was treated with Penicillin 2 million units I. V. 6 hourly and Streptomycin 0.75 grams IM daily. When the blood culture was reported as growing *Neisseria meningococcus* (Dr. Rohini Abeysuriya, Consultant, Microbiologist, General Hospital, Colombo) the treatment was continued for 18 days. The response was satisfactory with the fever settling in 3-4 days. The patient was discharged for out patient therapy 19 days after admission.

### Discussion

Several reviews have remarked on the changing pattern of infective endocarditis. Vogler, Dorney and Bridges<sup>1</sup> reporting from Emory Hospital, Georgia for the period 1948-1960 review 148 cases of which 34 cases all under 40 years had congenital heart lesions. Nearly two thirds were due to Staphylococci or Streptococci. No case was due to a *Neisseria* organism. From the Presbyterian Hospital in New York, for the period 1938-1967, Cherubin and Neu<sup>2</sup> reported 655 cases. Congenital heart disease accounted for 6.8% cases. Between 1938-1942 there were 6 cases due to *Neisseria* organisms of which only 1 case was due to *N. meningococcus*. After 1942 there

were no cases due to *Neisseria*. At the University of Minnesota Hospital, Pankey<sup>3</sup> reviewed 221 cases from 1939-1959. There were no cases due to *Neisseria* organisms. In 1966, Lerner and Weinstein<sup>4</sup> reported 100 cases from a Boston hospital for the preceding 9 years and no case of *Neisseria* endocarditis was seen for this period and they quote that in the past *N. gonococcus* was responsible for 4-10% of infective endocarditis. From another Boston hospital, Finland and Barnes (1970)<sup>5</sup> reviewed 337 cases for the 12 year period 1933-65. Only 1 case of *N. meningococcal* endocarditis was seen and that in 1933. These authors note that with introduction of the first potent antibiotic in 1935 there has been a marked change in the nature of the infecting organisms, less *Streptococci viridans*, *Streptococcus pyogenes* and *Staphylococci* being seen in the later half of this period. Macdonald<sup>6</sup> notes that *Streptococci* still continue to be an important infecting organism accounting for 60-80% of all cases and cautions that *Streptococcus viridans* are a diverse group not all showing alpha haemolysis. The alpha haemolytic types like *S. sanguis* and *S. mitis* are responsible for 50% of all *Streptococcal* endocarditis while non haemolytic types like *S. mutans* and *S. bovis* are responsible for 35% and enterococci (*S. faecalis*) contribute 10%.

More recently the reappearance of *Neisseria* endocarditis, and that due to commensals like *N. catarrhalis* and *N. sicca* have been associated with the disease occurring on prosthetic valves.<sup>8 9</sup>

The rarity of infective endocarditis with atrial septal defect and in cyanotic heart disease has been known for a long time<sup>10 11</sup> with the occasional case found in ostium primum defects.<sup>12</sup> A high differential pressure across a defect is necessary to produce a jet or turbulence<sup>13</sup> which in turn causes minute thrombi to form on abnormal endocardium and



if there is a bacteremia organisms adhere to the platelet thrombi producing a friable vegetation. Such pressure differences do not occur in uncomplicated interatrial septal defects. In the management of infective endocarditis blood cultures are of great importance in selecting the proper therapy. Fungal infections are not primary. They may follow cardiac surgery, complicate antibiotic therapy or develop in patients on immunosuppressive drugs. Fungal spores almost always gain access to the body through intravenous drips.

Except in cases treated partially with antibiotics, bacteraemia is constant so that 4-6 cultures in 1-2 hours should be taken.<sup>7</sup> It is unnecessary to take any more. The duration of treatment depends on (i) the infecting organism (ii) duration of symptoms before treatment (iii) rapidity of response and (iv) whether prosthetic valves or other foreign material are present in the heart. The minimum duration should be 3 weeks. With artificial valves the course should extend to 6 weeks. If the infection is due to a fungus and a valve is involved, excision of the valve is necessary because of the low efficacy of antifungal drugs and the high incidence of toxicity with these drugs.

Any drug prescribed must be bactericidal and if given intravenously should be by bolus injections. This is surer to obtain peak levels and avoids inactivation by the infusion fluid.

In most medical cases treatment is best started, after cultures are taken, with Penicillin G 10 million Units/24-hours and an aminoglycoside like gentamicin 80mg 8 hourly. If the culture grows *Streptococcus viridans* Penicillin alone should be sufficient. It is prudent to add erythromycin in the last week of treatment to kill any organisms which have become penicillin resistant. Probenicid is to be avoided as it tends to increase the penicillin concentration without

reaching the peaks which should be at least 6 times the in vitro lethal concentrations.

*Streptococcus faecalis* resistant to Penicillin and streptomycin singly, may respond to a combination of both because of their synergistic effect. Instead gentamicin may also be used, the dose being dependent on the presence of eight nerve toxicity. Ideally blood level between 5mg/ml and 14 mg/ml has to be achieved. For both *Staphylococcus albus* and *aureus* Penicillin G may be used if the organisms are sensitive. Since most strains are resistant because of penicillinase production, Cloxacillin or Fluoxacillin in combination with Fusidic acid should be given. An alternative is the use of cephalosporins eg. Cephaloridine, Cephalothin or Cephazolin.

Culture negative endocarditis usually due to recent antibiotic therapy. But this may be also due to infections by *Coxiella* or *Chlamydia* which are cell dependent and therefore diagnosed serologically. For these Tetracycline 2 gram t.d.s. orally decreasing to 250 mg t.d.s., once there is clinical improvement, is best. Some cases are best dealt surgically. Otherwise, in culture negative endocarditis an infection by *Streptococcus viridans* or *faecalis* is assumed and the appropriate antibiotics given.

For Gram negative organisms a combination of two antibiotics should be given. One should be an aminoglycoside, preferably gentamicin, and the other chosen from amongst Penicillin G, ampicillin, arpicillin or a cephalosporin.

A fungal infection (candida, aspergillosis) should be suspected in patients on steroids, broad spectrum antibiotics, immuno suppressants who are having prolonged intravenous infusions. Blood cultures are negative delaying the diagnosis. The drugs which are used, Amphotericin and Flucytosine are not



only highly toxic to the liver and kidney but are fungistatic rather than fungicidal.

Where facilities are available there is an increasing role for surgical management particularly in fungal and other difficult to eradicate infections, infection supervening on prosthetic valves and for haemodynamic reasons e.g. rupture of valve.

### Summary

A case report of infective endocarditis is reported which showed two unusual features (i) The rarity of the infecting organism, *Neisseria meningococcus* and (ii) the rarity of the cardiac lesion, uncomplicated atrial septal defect.

The management of infective endocarditis is briefly discussed.

### References

1. Vogler W. R. Dorney E. R. and Bridges H. A. Bacterial Endocarditis. A review of 148 cases. *American Journal of Medicine*. (1962) 32, 910-921
2. Cherubim C. E. and Neu H. C. Infective endocarditis at the Presbyterian Hospital in New York City from 1938-1967. *American Journal of Medicine* (1971) 51, 83-96.
3. Pankey G. A. Acute bacterial endocarditis at the University of Minnesota hospitals. 1939-1959. *American Heart Journal* (1962) 64, 583-591.
4. Lerner P. L. and Weinstein L. Infective endocarditis in the antibiotic era. *New England Journal of Medicine* (1966) 274, 199-206.
5. Finland M. and Barnes M. W. Changing aetiology of bacterial endocarditis in the anti bacterial era; experience at Boston City Hospital 1933-1965. *Annals of Internal Medicine* (1970) 72, 341-348.
6. Macdonald A. Management of Infective endocarditis. *British Journal of Hospital Medicine* (1979) 21, 498-506.
7. Oakeley C. Treatment of endocarditis. *British Medical Journal* (1978) 2, 489-490.
8. Ghoneim A. T. M. and Tandon A.P. Prosthetic valve endocarditis due to *Neisseria Siccia*. *Indian Heart Journal* (1979) 31, 246-248
9. Pollock A. A. and Holzman R. S. *Neisseria catarrhalis* endocarditis. *Annals of Internal Medicine* (1976) 85, 206-207.
10. Vogler W. R. and Dorney E. R. Bacterial Endocarditis in congenital heart disease. *American Heart Journal* (1962) 64, 198-206
11. Gelfman R. and Levine S. A. Incidence of acute and subacute bacterial endocarditis in congenital heart disease. *American Journal of Medical Science* (1943) 204, 324-333
12. Hayward G. Diagnosis of bacterial endocarditis. *Proceedings Royal Society of Medicine*. (1960) 53, 351-354
13. Hamer J. and Shaw E. Infective endocarditis. *Medicine* (1979) Aug. 20, 1030-1033



## HAEMOPHILIA IN A SRI LANKAN FEMALE

N. NAGARATNAM, J. WIJESEKERA, SARVANANTHESWARI SINNADORAI  
and K. MOHANARUBAN*General Hospital, Colombo.*

A Sri Lankan Sinhalese female with five children was seen with swelling of her right hand, forearm and her left shoulder. The overlying skin was ecchymotic. She gave a history of similar episodes together with abnormal bleeding tendency. She had a contracture of her right elbow joint. Radiological examination of the elbow joint revealed changes consistent with haemarthrosis. The diagnosis of classical haemophilia due to factor VIII deficiency was documented by prolonged clotting

Her parents were first cousins (Fig.). Her father (III-4) a known bleeder, her two sisters (IV-5 and IV-6) and her son (V-16) were examined and were found to have factor VIII deficiency.

Haemophilia is uncommon in the female. It is usually not possible to ascertain if a female is a carrier of haemophilia unless she has a haemophiliac son or is a daughter of a haemophiliac father. In a comprehensive review, Afifi<sup>1</sup> could cite only 24 published cases. Four

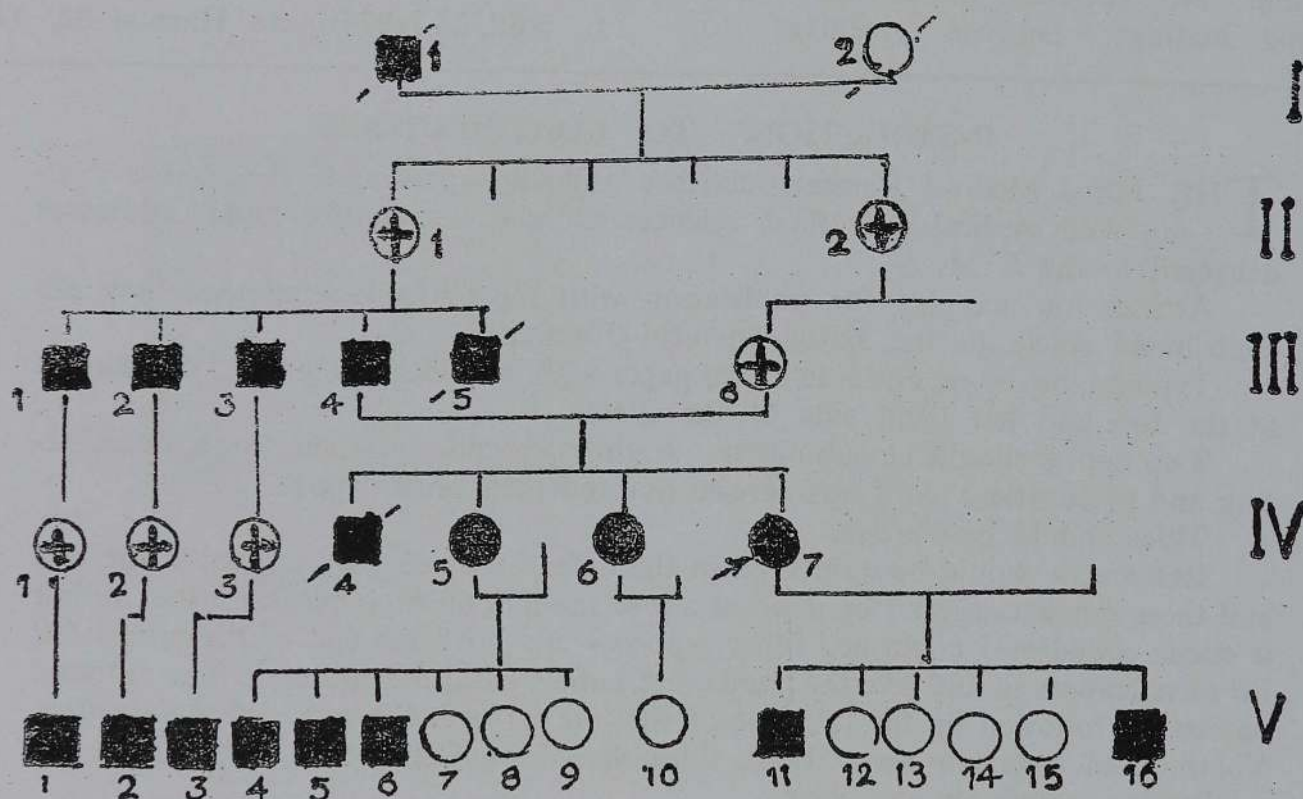


Fig. Family tree

■ male bleeder    ● female bleeder    + female carrier  
○ normal female    ↑ proband

time, normal prothrombin time and abnormal thromboplastin generation test. The index case was subject IV-7. Her grandfather was a known bleeder (I-1). of them were true sporadic haemophilia in apparently normal females. Seven cases were truly homozygous for the classic sex-linked recessive haemophiliac



gene and the product of bleeder-conductor marriage as in this study. The remaining 13 cases were assumed to be heterozygous and their manifestations of haemophilia were explained on either on a chance mutation producing a haemophilic gene on the 'X' chromosome inherited from the father or on the basis of Lyon's hypothesis.

Mutation from a normal gene to abnormal at any given locus takes place only one in 100,000 gametes, so that the likelihood of a female being a haemophilic is  $100,000 \times 100,000$ . However mating patterns are important in that there is a degree of consanguinity and inbreeding in the reported ethnic background. All societies have rules which forbid matings between relatives of

various kinds for there may be social and genetic consequences. The family organisation and marriage customs which formed the keystone of social and economic arch of these communities over several hundred years illustrate some basic genetic knowledge. The Sinhalese in common with the Tamils regard marriage with the maternal uncle's daughter or failing one a paternal's aunt's daughter as not merely proper or desirable but even obligatory, whereas marriage between two brothers or two sisters children is forbidden. In this family the father (III-4) of the proband (IV-7) had married his maternal aunt's daughter.

#### Reference

1. Afifi, M (1974) *Acta Haemat.* 82, 112

### INSTRUCTIONS TO CONTRIBUTORS

**T**HE Jaffna Medical Journal publishes original papers and case reports dealing with medical and allied sciences as well as lectures and addresses delivered to the J. M. A.

Articles are accepted for publication with the understanding that they are contributed solely to the Jaffna Medical Journal.

Typing must be on one side of the paper with double spacing and 5 cm margin at the top and left hand side of the sheet.

Two copies should be submitted. Authors should give their name, qualification and place where work was carried out and their present post.

Titles should be concise.

References should be numbered in the order in which they appear in the text and these numbers should be inserted above the line on each occasion the author is cited. (Andrew<sup>1</sup> confirmed other reports<sup>2-4</sup>). At the end of the article full list of references should give the names and initials of all the authors. The authors' names are followed by the full title of the journal with the year of publication. Volume and page numbers. Book titles should be followed by the place of publication, publisher and year.

Tables should be typed in double spacing and on separate sheets. Illustrations, graphs and line figures should be in black ink on plain white paper or bristol board. Glossy photographs should be supplied unmounted.

Legends and captions should be typed on a separate paper and numbered to correspond.

Papers should be sent to the Editor, Jaffna Medical Journal General Hospital Jaffna.

The statements contained in the articles are the sole responsibility of the authors and do not in anyway reflect the opinion or the attitudes of the J. M. A.



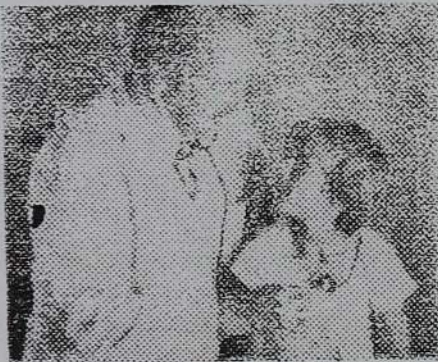
FOR A LIFETIME  
OF MEDICINE:

**Littmann**

STETHOSCOPES FOR  
PHYSICIANS



3M Medical Products represented  
in Sri Lanka by  
The Central Medical Stores Ltd.  
Main Street - Colombo 11




YOU'LL BE GLAD YOU  
CHOSE A

**Littmann** STETHOSCOPE

Whether it's the first stethoscope you buy during your student years, or a specialized instrument purchased later, you will appreciate the convenience, the performance and the pride of owning a LITTMANN Stethoscope. From the full line of precision LITTMANN instruments, you can make a personal and professional choice that exactly suits your needs.

ALL LITTMANN Stethoscopes feature a binaural fixed at the anatomically correct angle and offer ear tips in four sizes for proper fit, comfort and freedom from room noise interference.

3M Medical Products represented  
in Sri Lanka by  
The Central Medical Stores Ltd.  
Main Street - Colombo 11.





The Pfizer Research Product

**Fasigyn**<sup>\*</sup>  
TINIDAZOLE

500 mg.







a new three day dosage regime for

**amebiasis**

With single 2 gram daily dose

Proven Amebicidal Activity

**ENSURES A PARASITOLOGICAL CURE**

DAY 1	DAY 2	DAY 3
single daily dose 	single daily dose 	single daily dose 
		

Fasigyn provides remarkably effective treatment in amebic dysentery and other forms of acute and chronic amebiasis

<sup>\*</sup>Trademark



PFIZER LIMITED  
688, Galle Road, Ratmalana.



## News & Notes

**Jaffna Medical Association :** At the Annual General Meeting held on 21st of April 1980 Dr. S. Wijeyarajah was elected President for the year 1980—81, and will assume office on July 1st. The following were elected as Trustees of the Association under the terms of the new constitution: Dr. S. A. Dharmalingam, Dr. T. Gangadharan, Dr. K. Nithiananthan, Dr. S. S. Senathirajah and Dr. Yogu Pasupati.

The other office-bearers for 1980—81 were also elected, all unanimously, which portends an ill wind for the Association whose members fear election or else do not wish to serve in any capacity.

In the programme for the period July 1st to 31st December 1980 the following meetings have been scheduled: On 20th September a seminar will be held on Amoebiasis. On 16th September Dr. N. Saravanabavanathan will deliver a lecture on Homicidal Poisoning and on 22nd November T. W. Hoffman Esqr. President of the Wild Life and Nature Protection Society of Ceylon will deliver an illustrated lecture on The Wild Birds of Ceylon. As from July 1st the weekly meetings will be held at 6-30 p. m. on Wednesdays in the Nurses Lecture Theatre, and there will in addition be a Saturday meeting once a month to accommodate strangers from afar.

The outgoing President, Dr. S. S. Senathirajah, M. R. C. O. G. will deliver his Presidential Address on 12th July 1980. The new President, Dr. S. Wijeyarajah will deliver his on March 1981, while the President-elect Dr. R. Ganeshamoorthy has under the terms of the constitution to give his Presidential Address in the first week of July 1981.

### NEW PROFESSORS AT UNIVERSITY OF JAFFNA

Dr. A. Vijayaragavan. M.B., F.R.C.S. (Eng.) — Surgery  
Dr. N. Sreeharan, M.D. (Cey.), Ph.D., M.R.C.P. (U.K.) — Medicine

Following have been elected Fellows of Royal College of Psychiatrists.

1. Prof. S. A. W. Dissanayake Dept of Psychiatry Faculty of Medicine, Colombo.
2. Dr. Satkunanayagam, Consultant Psychiatrist, Mental Hospital, Angoda.



# Maharaja Investments Limited

A NAME YOU CAN BANK ON

**NOW**

**offers you a**


**higher rate of interest**

**21**<sup>0</sup>/<sub>0</sub> Interest per annum for one year—  
Interest paid monthly.

**23**<sup>0</sup>/<sub>0</sub> Interest per annum for two years  
Interest paid monthly.

**25**<sup>0</sup>/<sub>0</sub> Interest per annum for two years—  
Interest paid on maturity.

*for excellent 'Photo Stat' Copies*  
-75 cts. EACH



**Maharaja Investments Limited**

122, K.K.S. ROAD, JAFFNA.

T'phone : 8267

MEMBER OF

**the maharaja organisation limited**

HEAD OFFICE :

54, BANKSHALL STREET, COLOMBO-11

T'phone: 23603-6



# Hepavit

the energizing and  
vitalizing health drink

With Vitamins  
**A. D. & C.**  
For Children  
& Adults

Take Hepavit as a health  
drink or nourishing thirst  
quencher. Hepavit has a  
pleasant passion fruit  
flavour too!

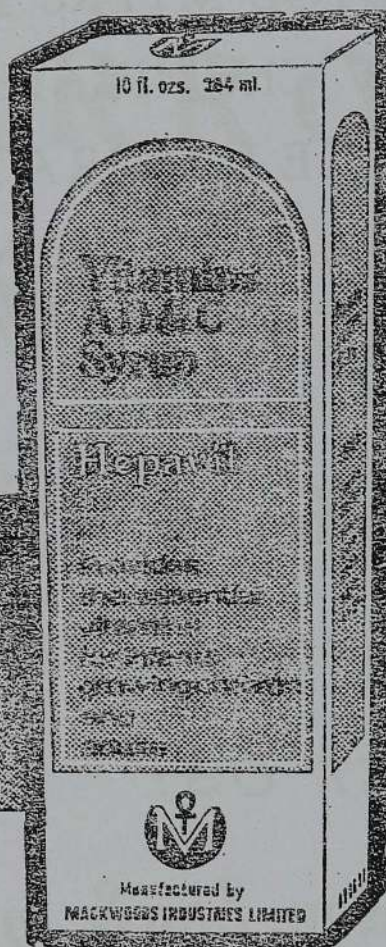

The new Hepavit  
for the whole family.



Manufactured by  
**Mackwoods Industries Ltd.,**

35, Madampitiya Road, Colombo 15. Telephone : 33381 - 2, 34080.





# PHARMACEUTICALS

FROM OUR EXCLUSIVE AGENCY LINES

- ⊗ ALCON LABORATORIES
- ⊗ BEECHAM RESEARCH INT.
- ⊗ BOEHRINGER MANNHEIM GMBH
- ⊗ BRISTOL MYERS INT.
- ⊗ DOW CHEMICALS INT.
- ⊗ SEARLE LABORATORIES
- ⊗ SMITH & NEPHEW LIMITED
- ⊗ SMITH & NEPHEW PHARMACEUTICALS  
LTD.

and for your requirements of  
**State Pharmaceuticals Corporation Drugs**

**CONTACT US :**

**J. L. Morison, Son & Jones (Ceylon) Limited**

P. O. BOX 430,  
50/1, COLLEGE STREET,  
COLOMBO—13.

Phone : 29645

---

FOR A FRIENDLY AND COURTEOUS SERVICE



ITS BACK AGAIN  
YOUR OLD FAVOURITE

# BAYFERRON

## Iron

## &

## Vitamin Tonic

*SOLE AGENTS:*

### Hayleys Limited

PHARMACEUTICALS & VETERINARY MEDICINES DEPT.,  
25, FOSTER LANE,  
COLOMBO—10.



INTRODUCING  
A NEW DRUG FOR THE TREATMENT OF  
LIVER DISEASE  
**CATERGEN**

(+) - Cyanidanol—3  
from the research Laboratories of

**ZYMA S.A. NYON-SWITZERLAND**

*Catergen offers genuine hepatotherapy*

- in acute viral hepatitis
- in alcoholic liver disease
- in toxic hepatitis
- in chronic persisting or aggressive hepatitis

*Prescribing information from the*  
**SOLE AGENT**

**Pettah Pharmacy Ltd.**  
WHOLESALE - RETAIL & DISPENSING CHEMISTS  
23, DAM ST., COLOMBO.12.

Phone: 31213 & 31214

Printed at St. Joseph's Catholic Press, Jaffna.















